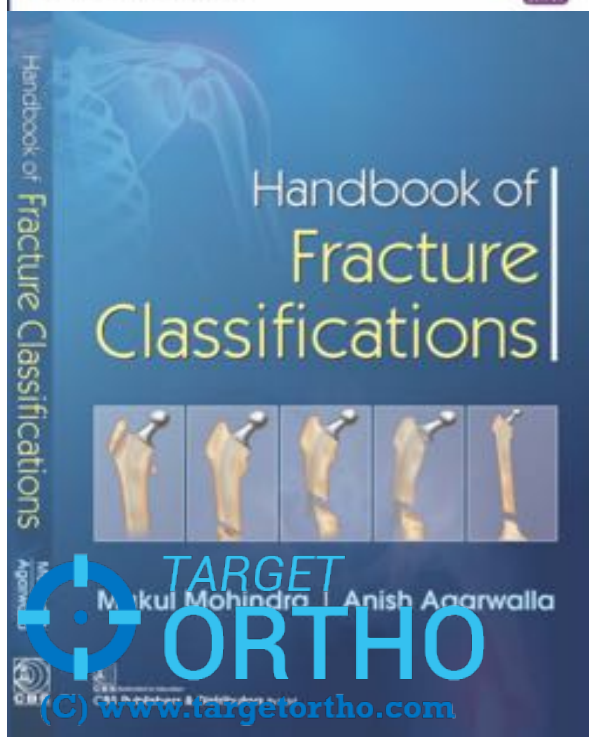


Mohindra • Jain



DR. MUKUL M  HINDRA

**mukulmohindra@gmail.com**

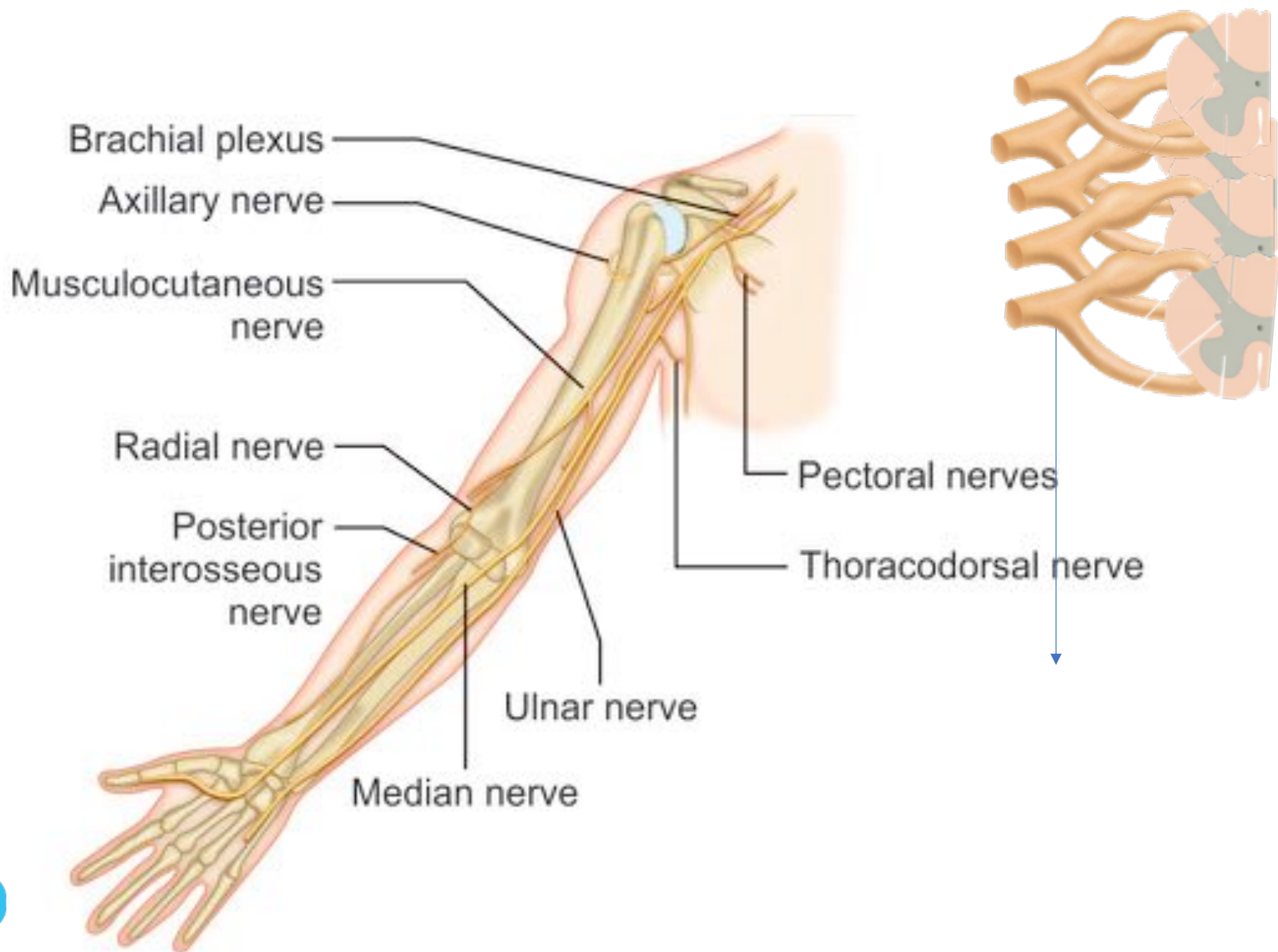
M.S [ORTHO], DNB, MNAMS

Diploma SICOT [Belgium]

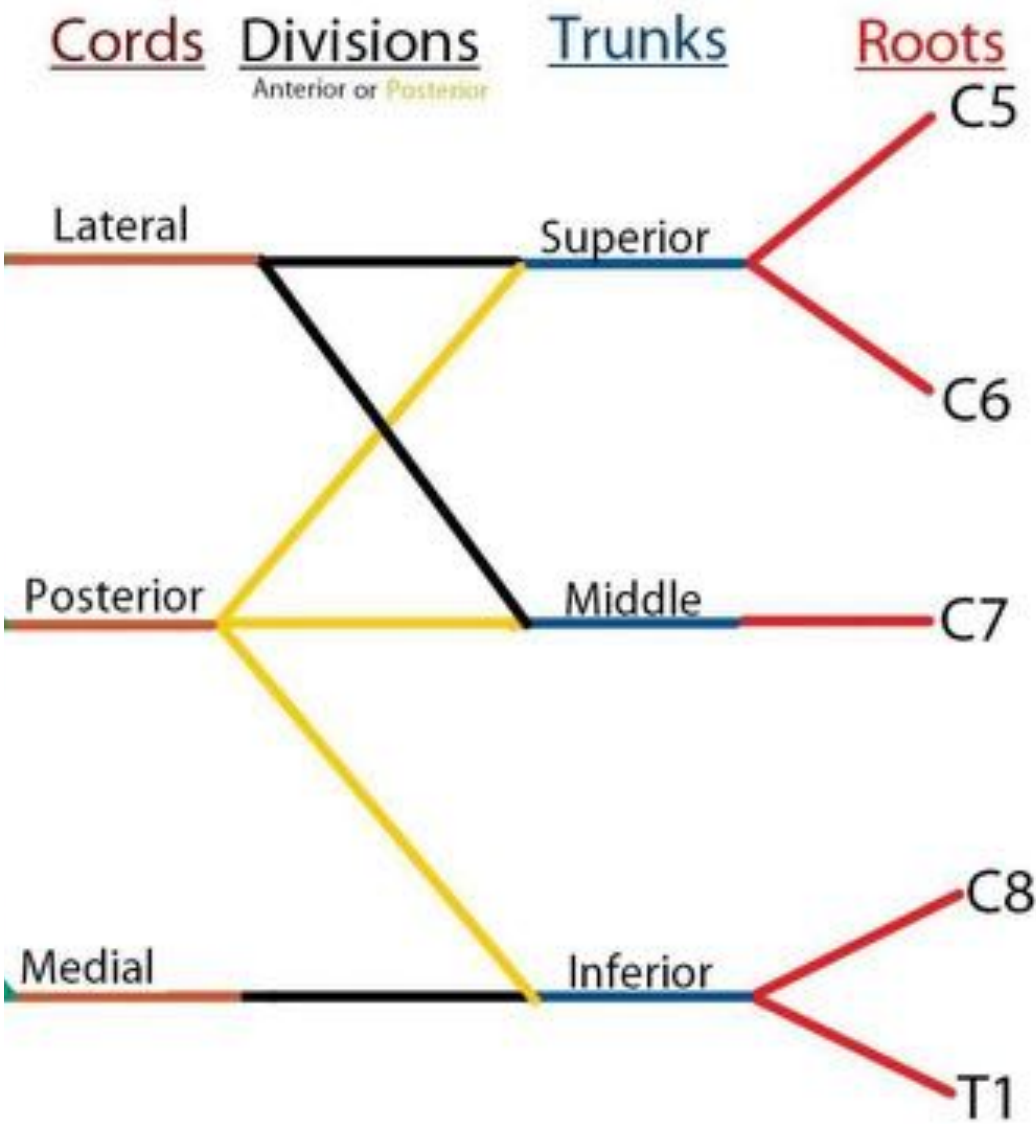
*FNB [Arthroscopy & Sports Medicine]*

*Fellowship in Minimally Invasive Arthroplasty (Athens)*

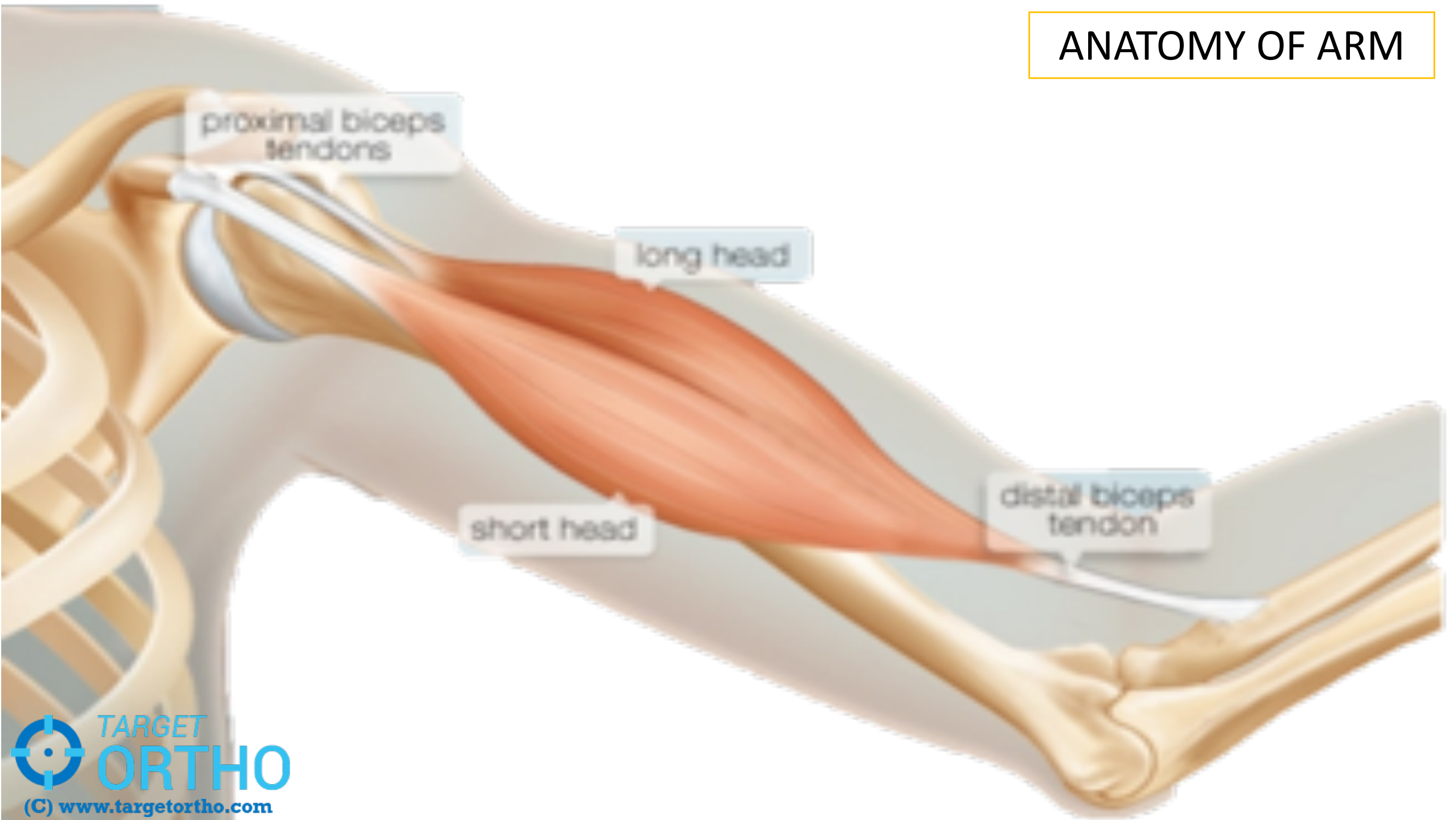
# PERIPHERAL NERVE INJURIES



# MACROSCOPIC ANATOMY



# ANATOMY OF ARM



*FRONT*

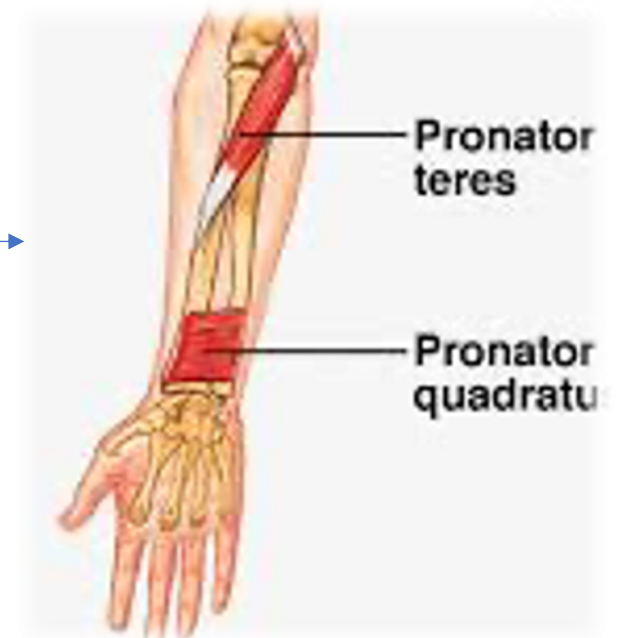
## ANATOMY OF FOREARM

*BACK*

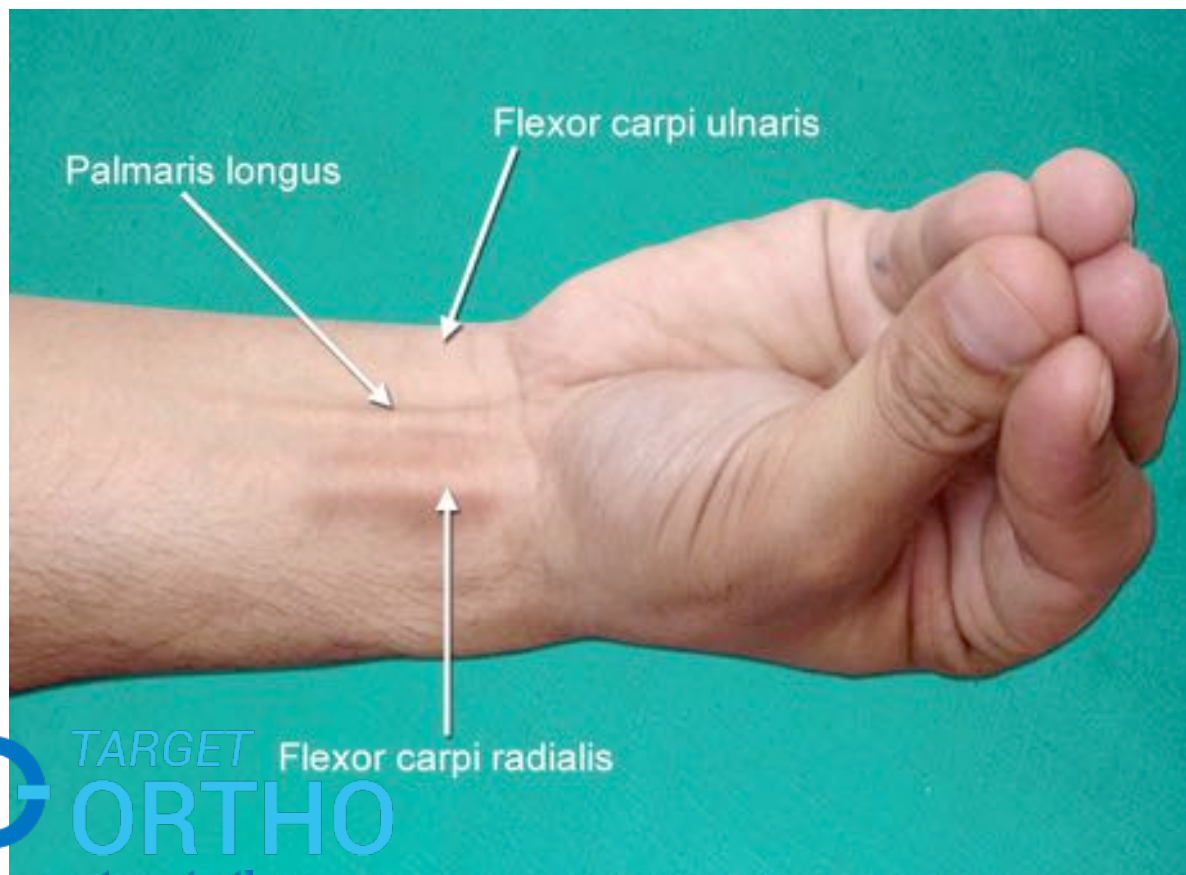
EXTENSORS

FLEXORS

PRONATORS



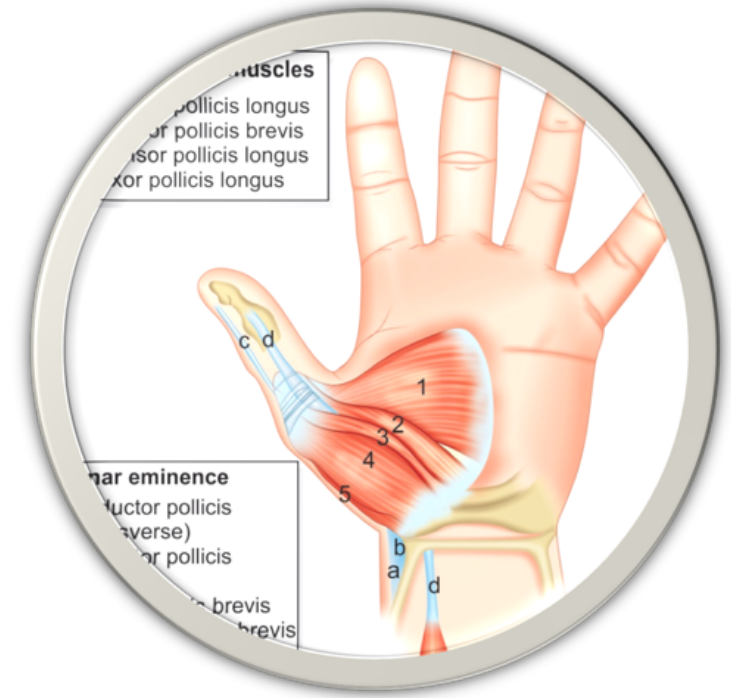




# ANATOMY OF HAND

THENAR  
MUSCLES

HYPOTHENAR  
MUSCLES

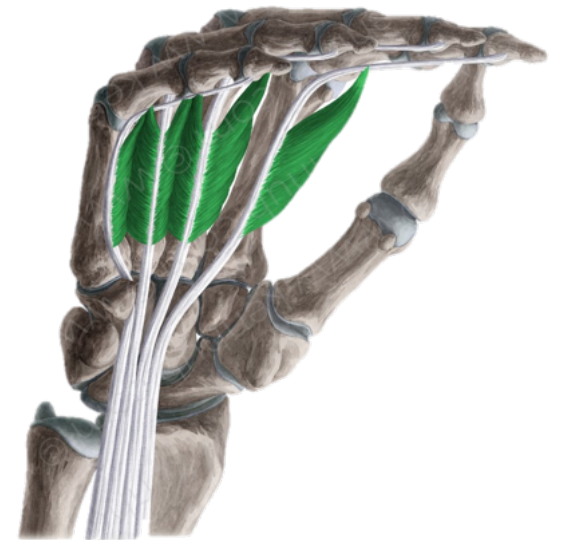



# ANATOMY OF HAND

INTER-OSSEI

LUMBRICALS



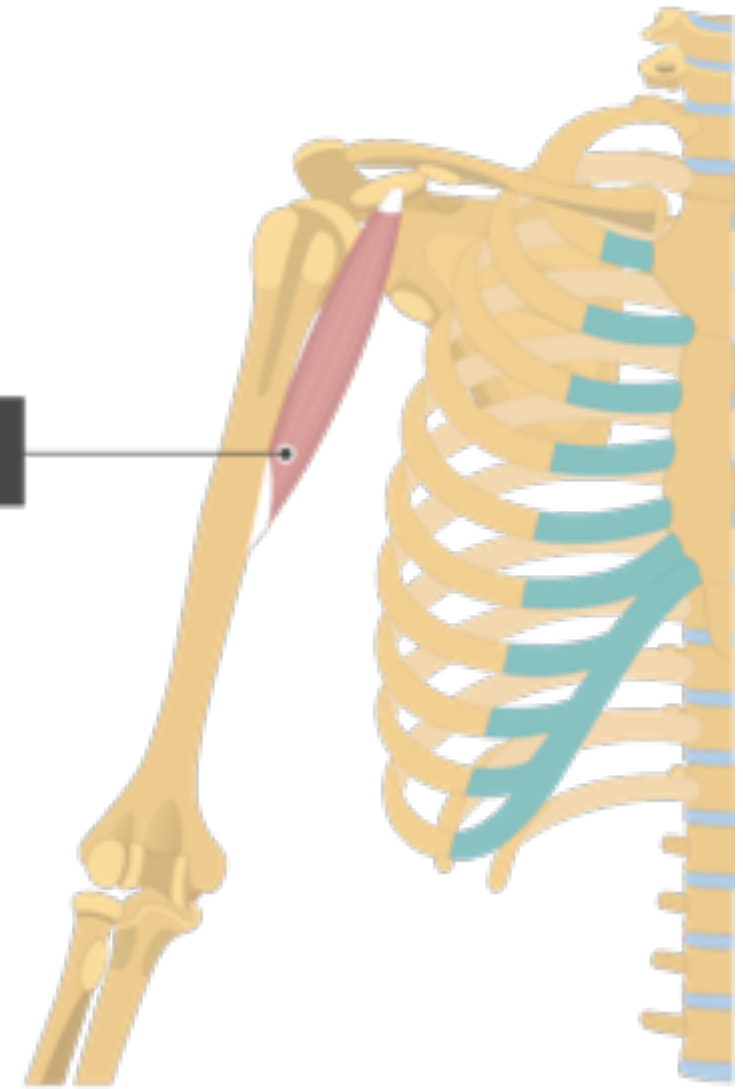
# ULNAR NERVE



# MNEMONICS



Coracobrachialis



## SITES OF COMPRESSION

MNEMONIC

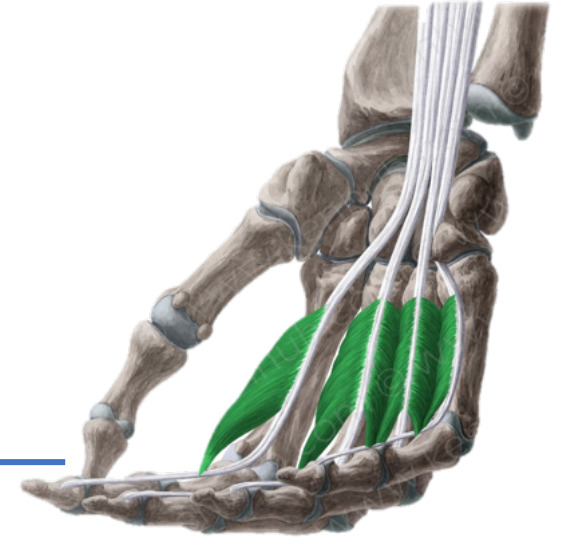
---

## MUSCULAR SUPPLY



Labourer's Nerve

Musician's Nerve



---

Q. Why is \_\_\_\_\_ nerve called Musician's Nerve?

## HIGH Vs LOW PALSY

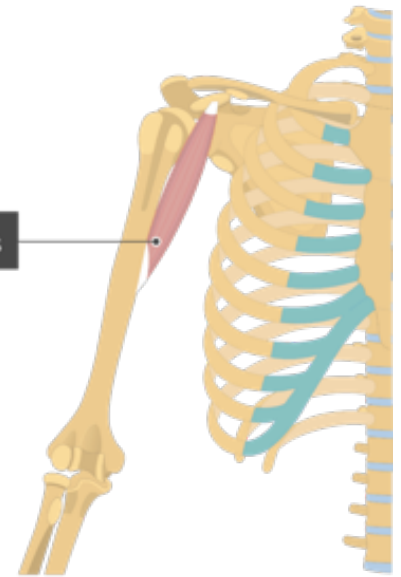
# MEDIAN NERVE



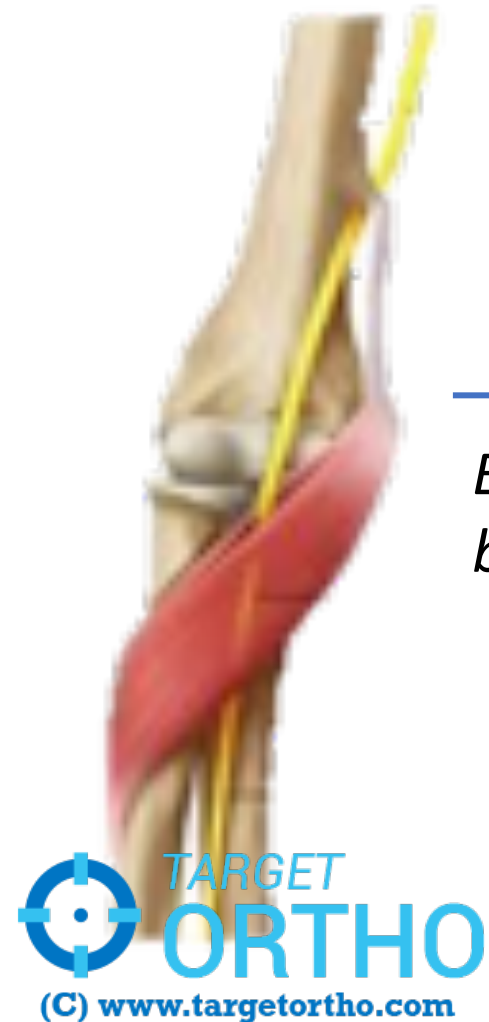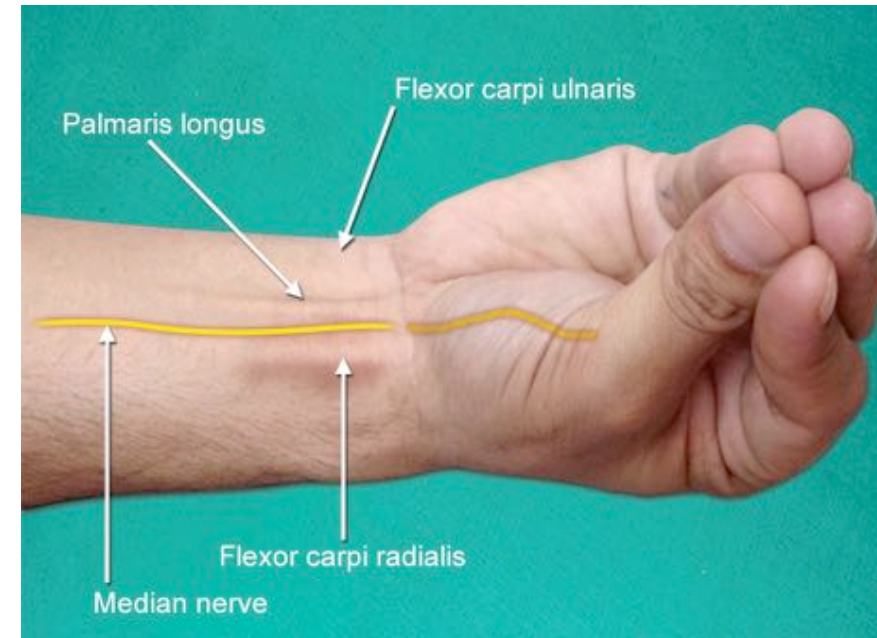
## MNEMONICS

*Every nerve changes its compartment at Coracobrachialis insertion!*

Coracobrachialis



*Every nerve enters the forearm between two heads of a muscle!*



## SITES OF COMPRESSION



## MUSCULAR SUPPLY

## MNEMONICS

*ALL FLEXORS OF FOREARM  
ALL THENAR MUSCLES OF HAND*

**MEDIAN NERVE**

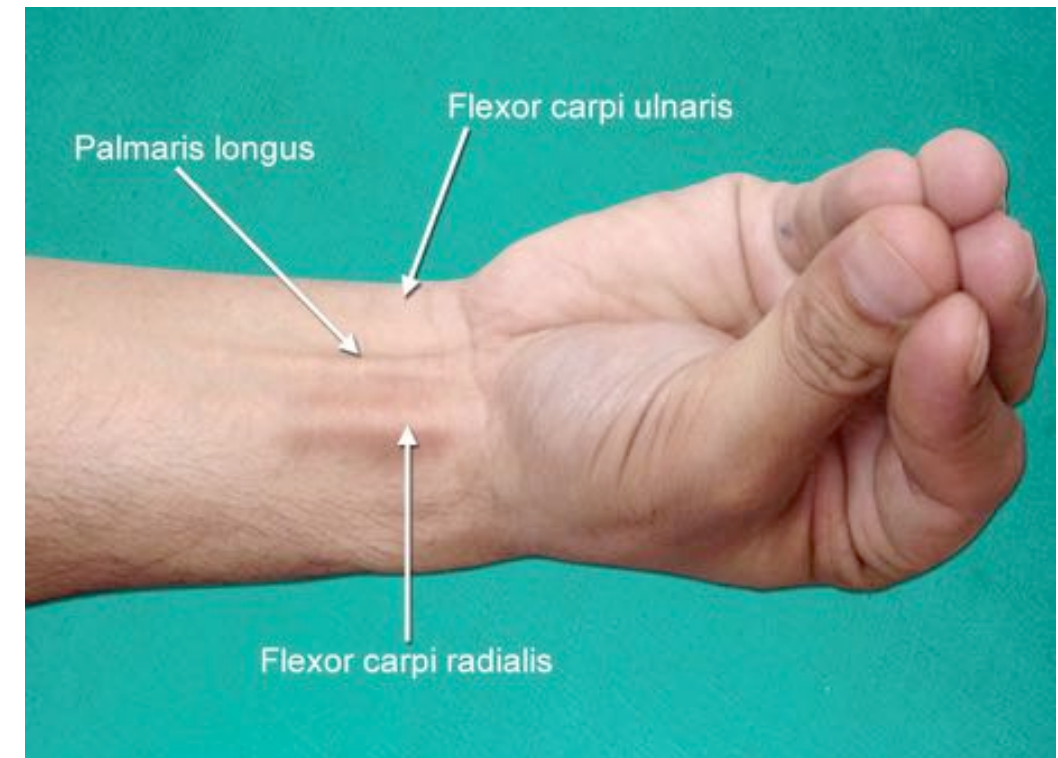
*EXCEPT ONE AND A HALF*

**ULNAR NERVE**

**FLEXORS**

*DEEP (FINGER) FLEXORS*

*SUPERFICIAL (WRIST) FLEXORS*



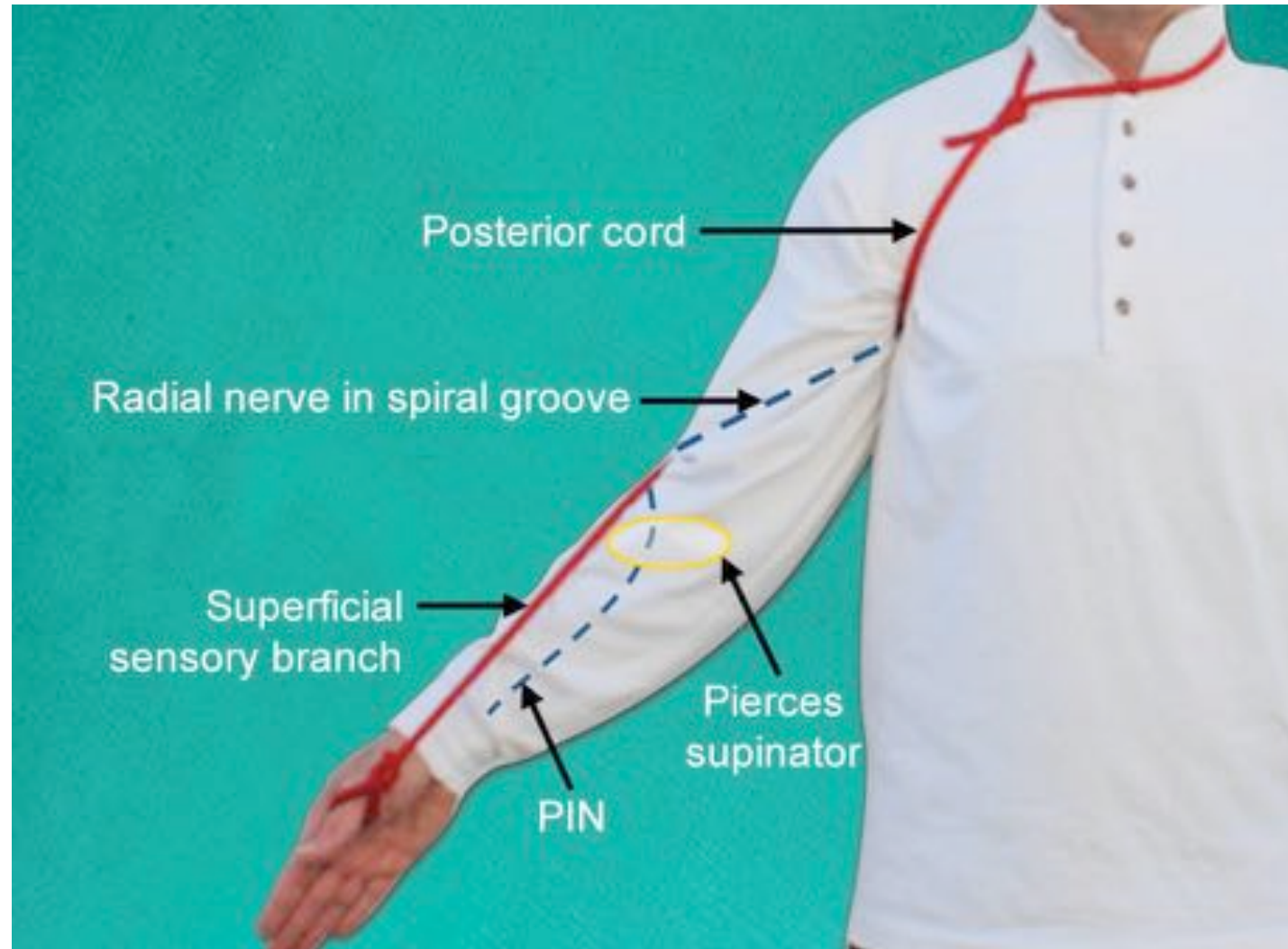
## CLAW HAND



## HIGH Vs LOW PALSY

## QUERIES

# RADIAL NERVE





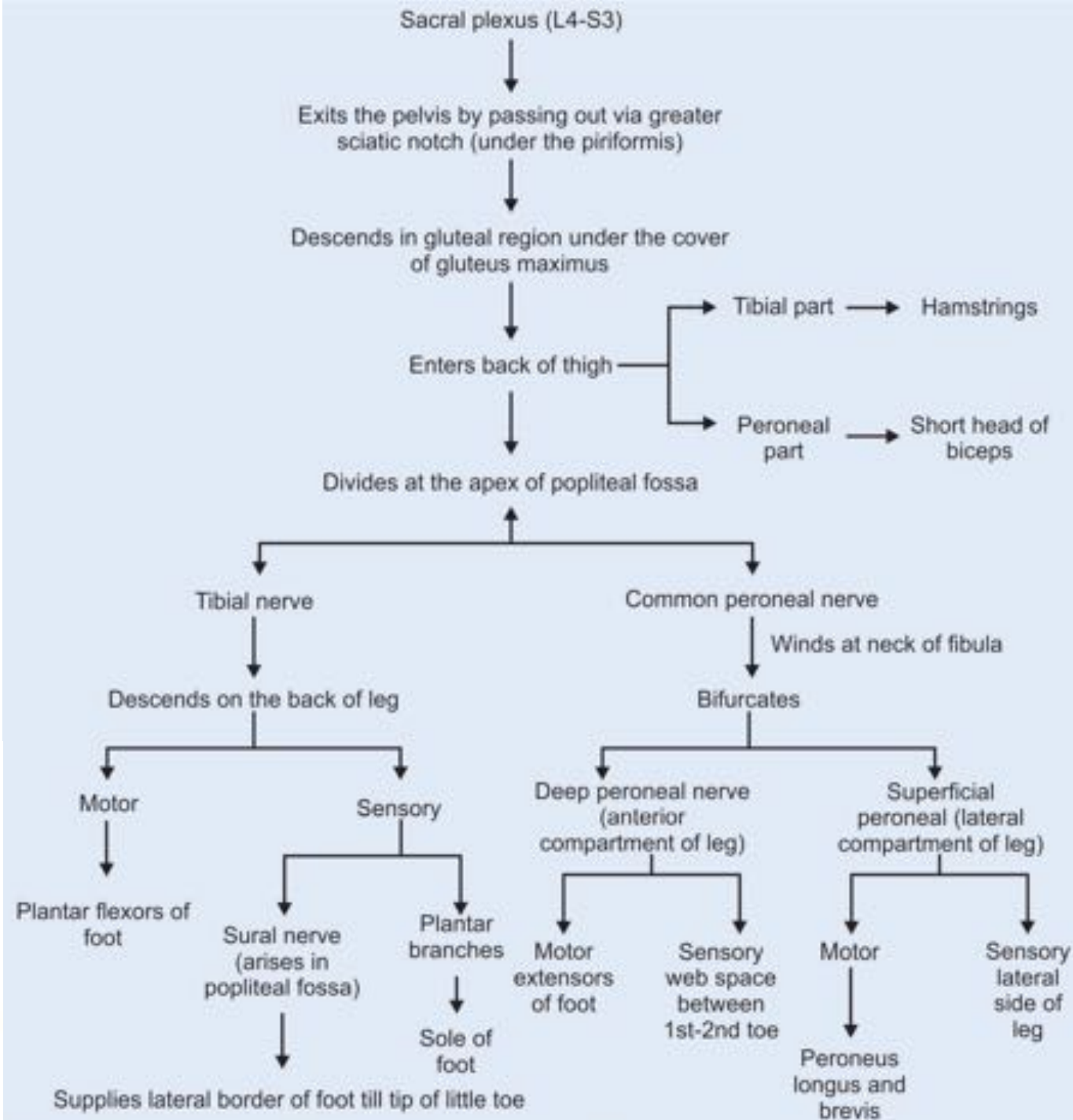
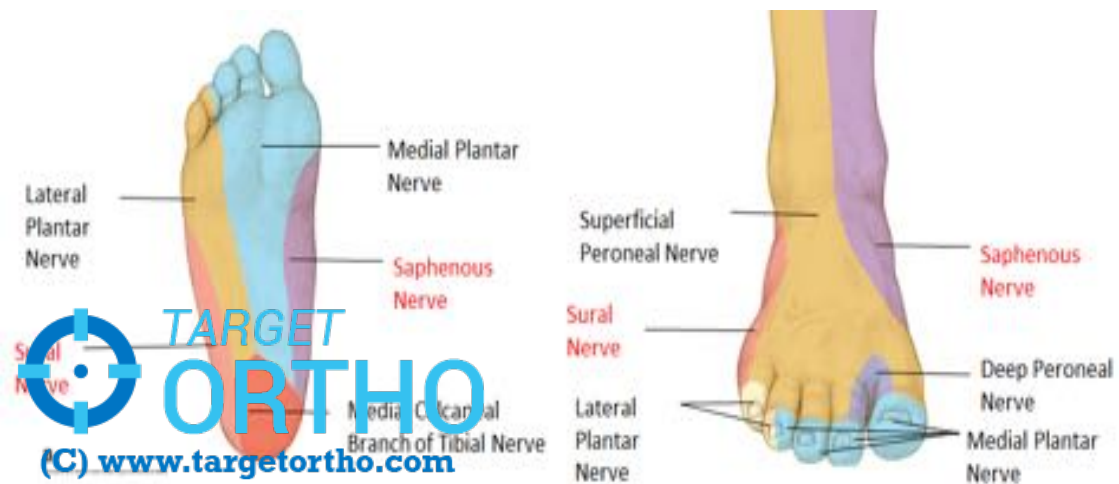
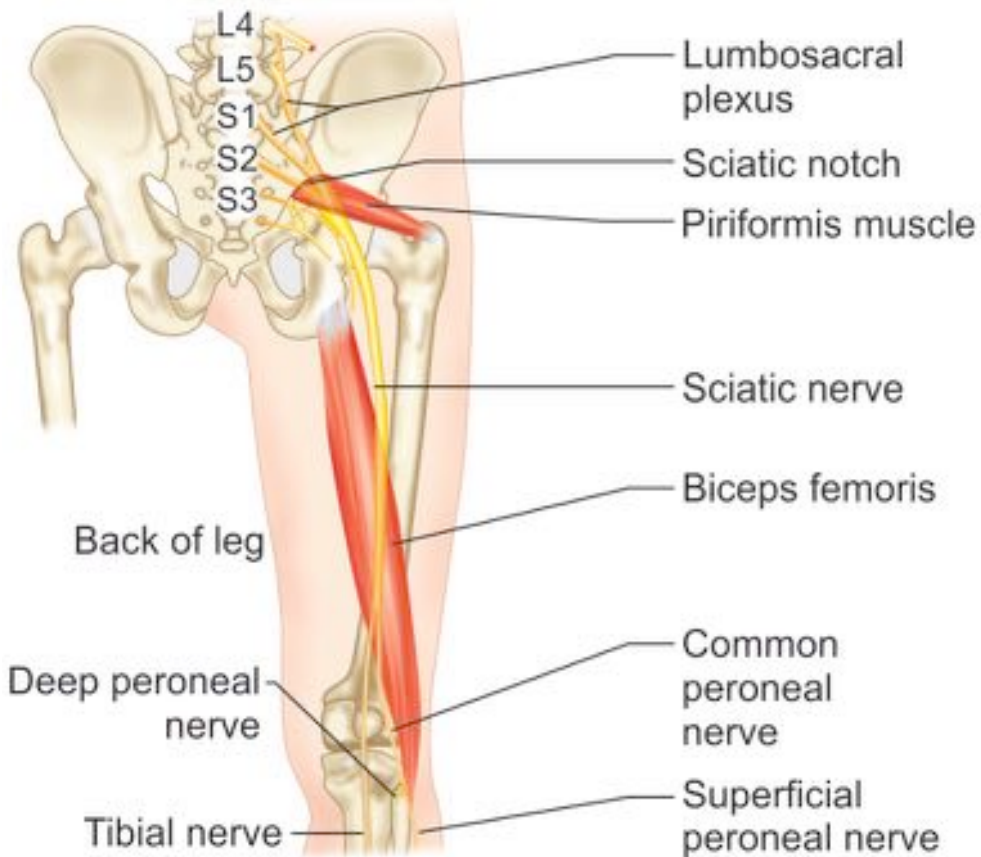


## MUSCULAR SUPPLY












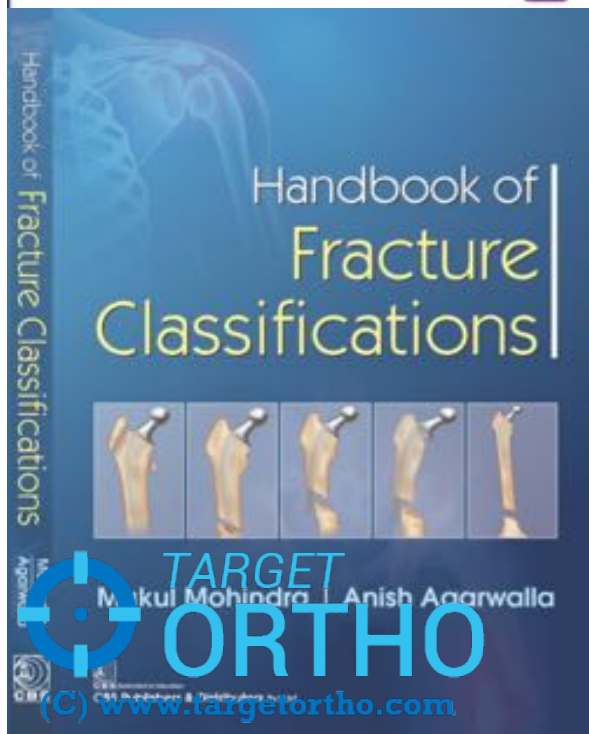








Mohindra • Jain



DR. MUKUL M  HINDRA

**mukulmohindra@gmail.com**

M.S [ORTHO], DNB, MNAMS

Diploma SICOT [Belgium]

*FNB [Arthroscopy & Sports Medicine]*

*Fellowship in Minimally Invasive Arthroplasty (Athens)*