

Osteotomies around Spine

Osteotomies around Spine

TABLE 80.4 Osteotomies in Spinal Deformity Surgery

Soft tissue/ligament releases

Ponté osteotomy (facet-based osteotomy in the *unfused* spine)

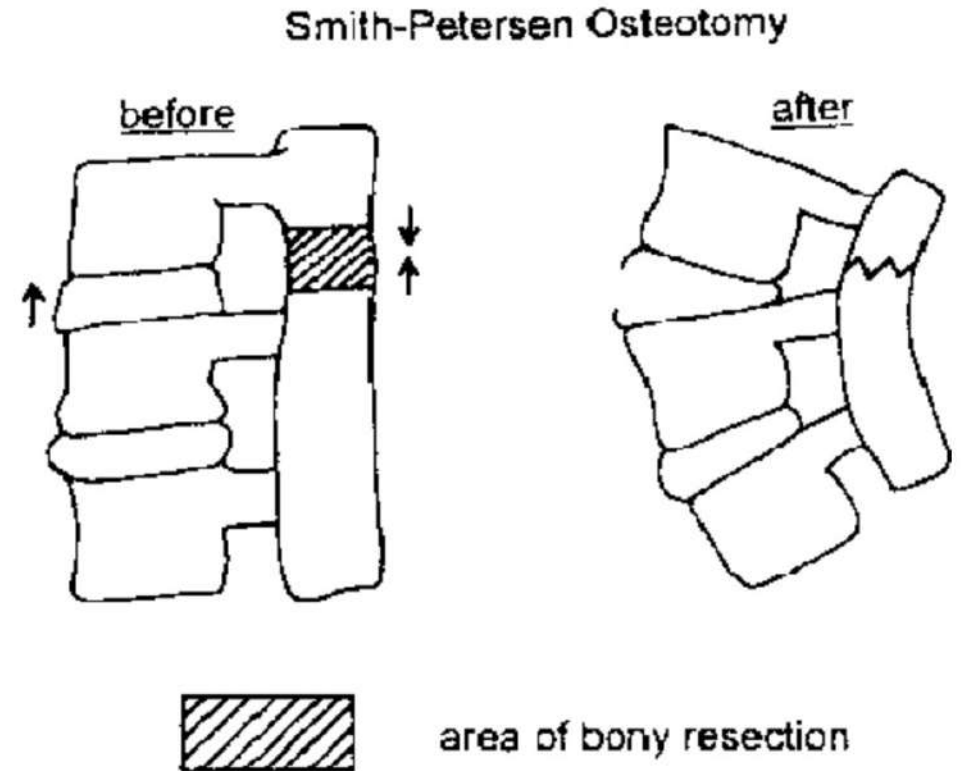
Smith–Petersen osteotomy (facet-based osteotomy in the fused spine)

Pedicle subtraction osteotomy

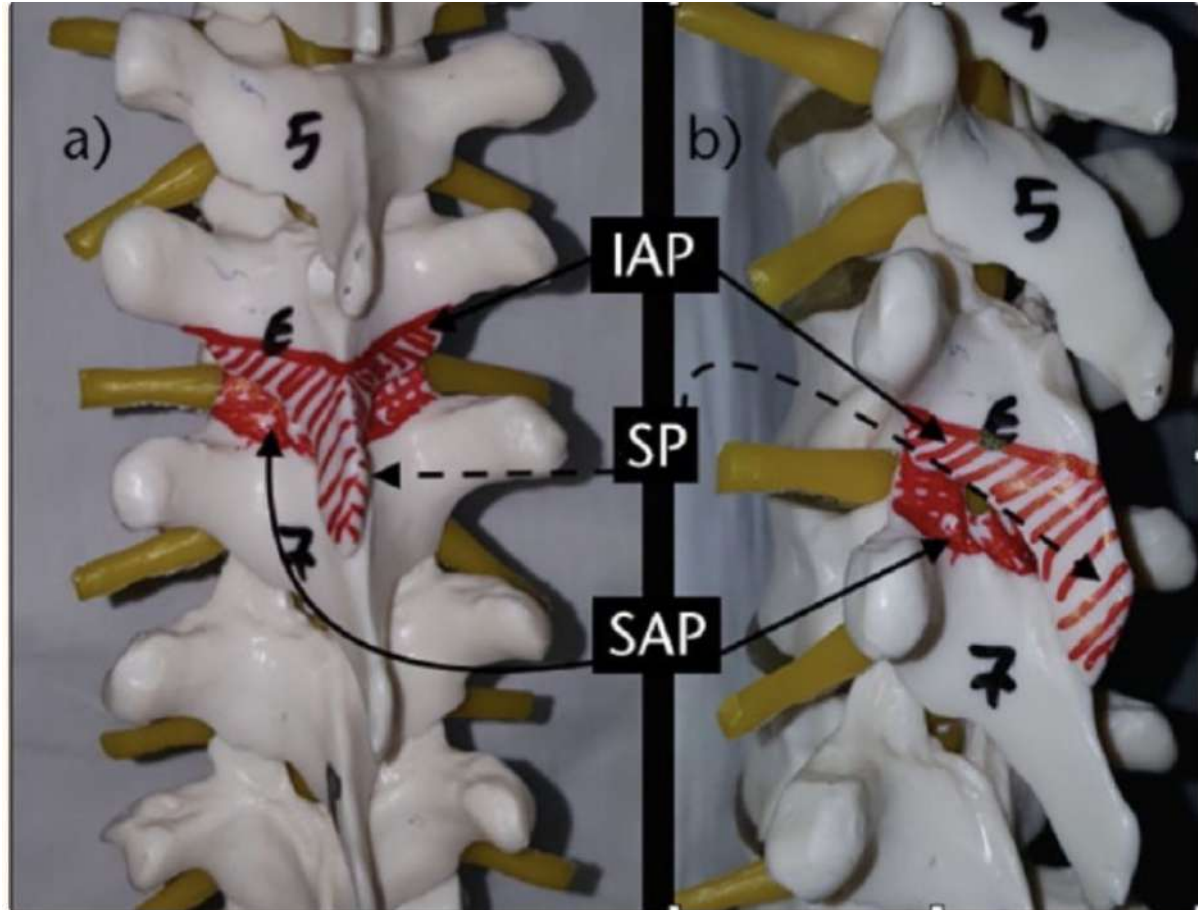
Vertebral column resection

Smith Petersen Osteotomy

- Posterior column osteotomy
 - Posterior ligaments
 - Facet Joints
- Correction through disc space
- Pre-requisite: Mobile anterior disc

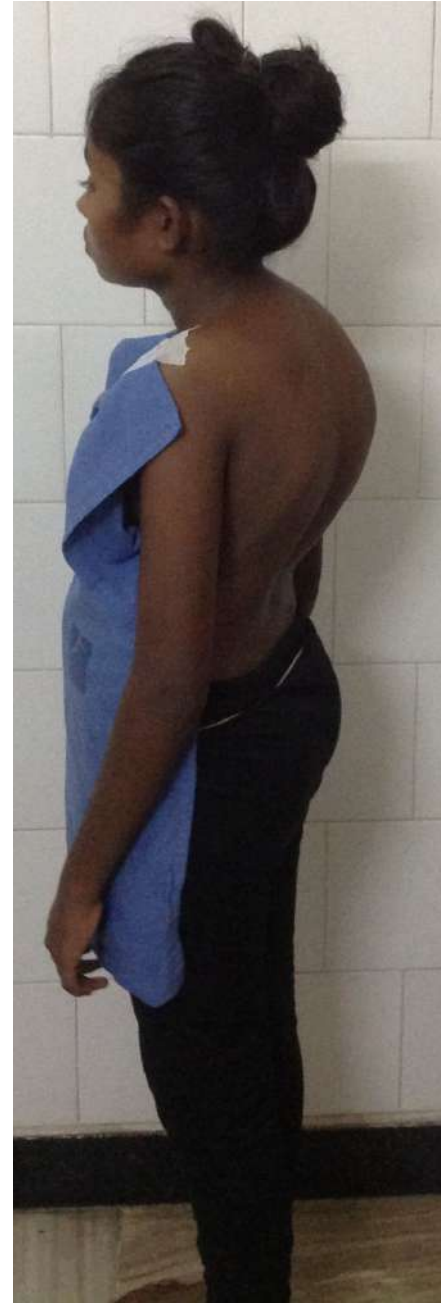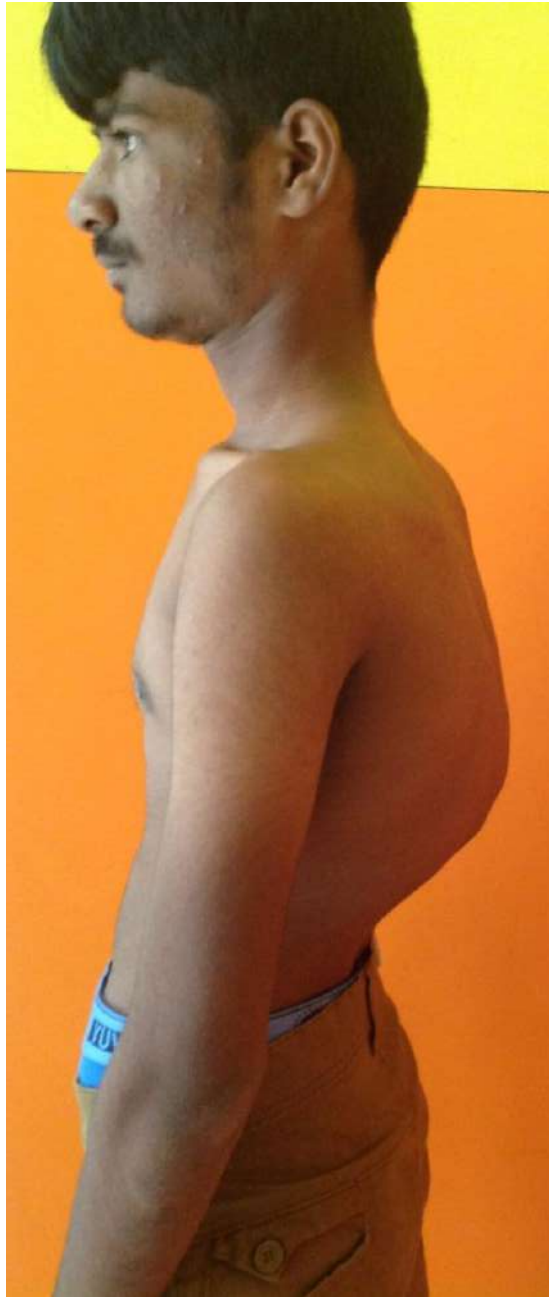

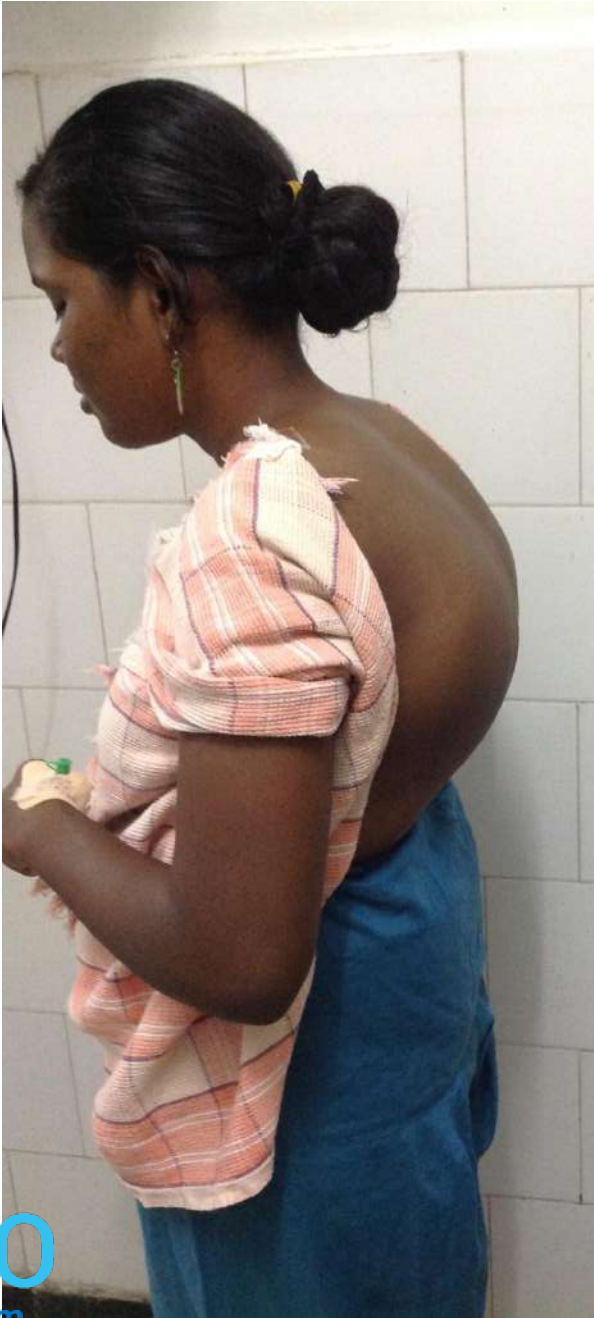
Smith Petersen Osteotomy

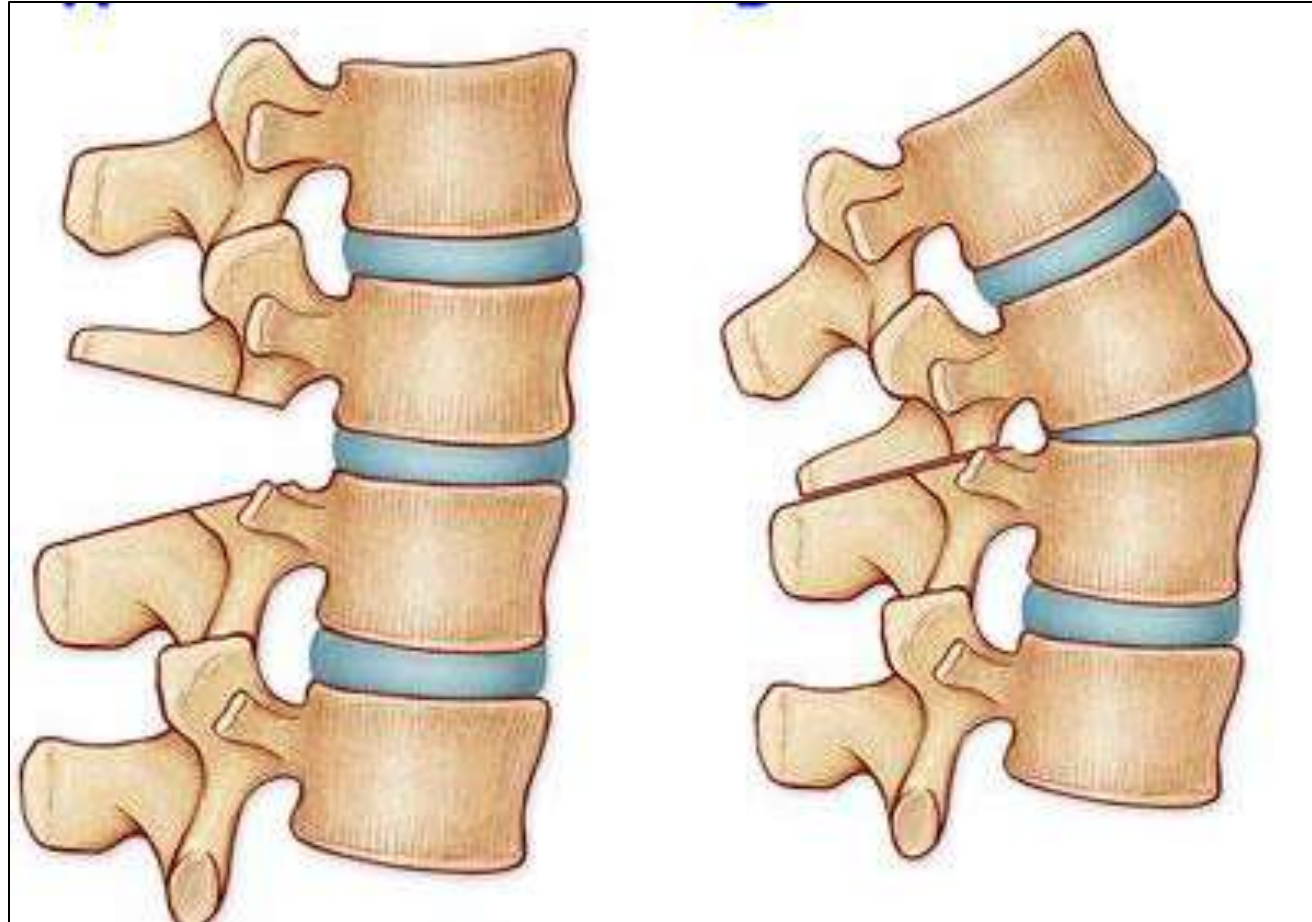


Smith Petersen Osteotomy

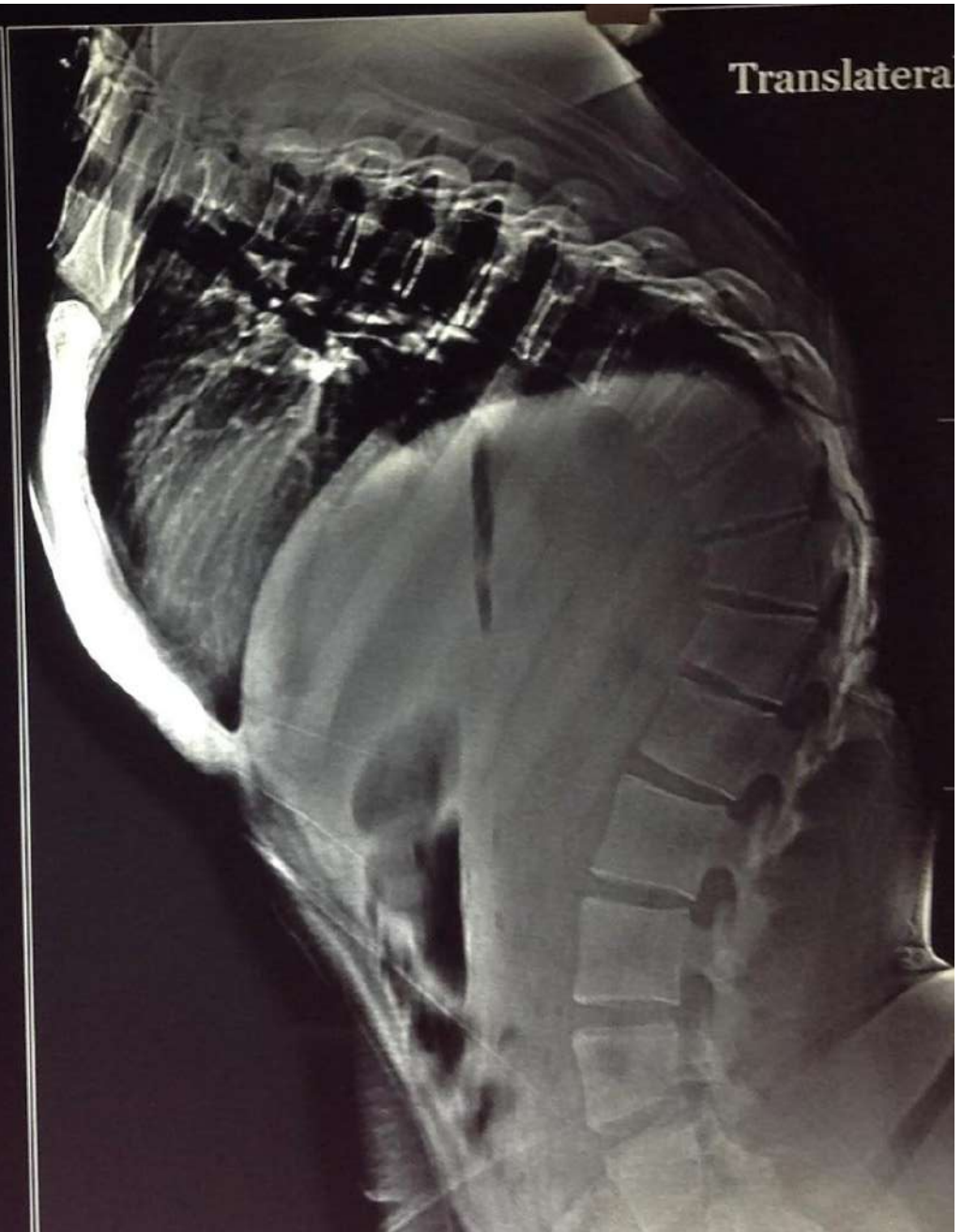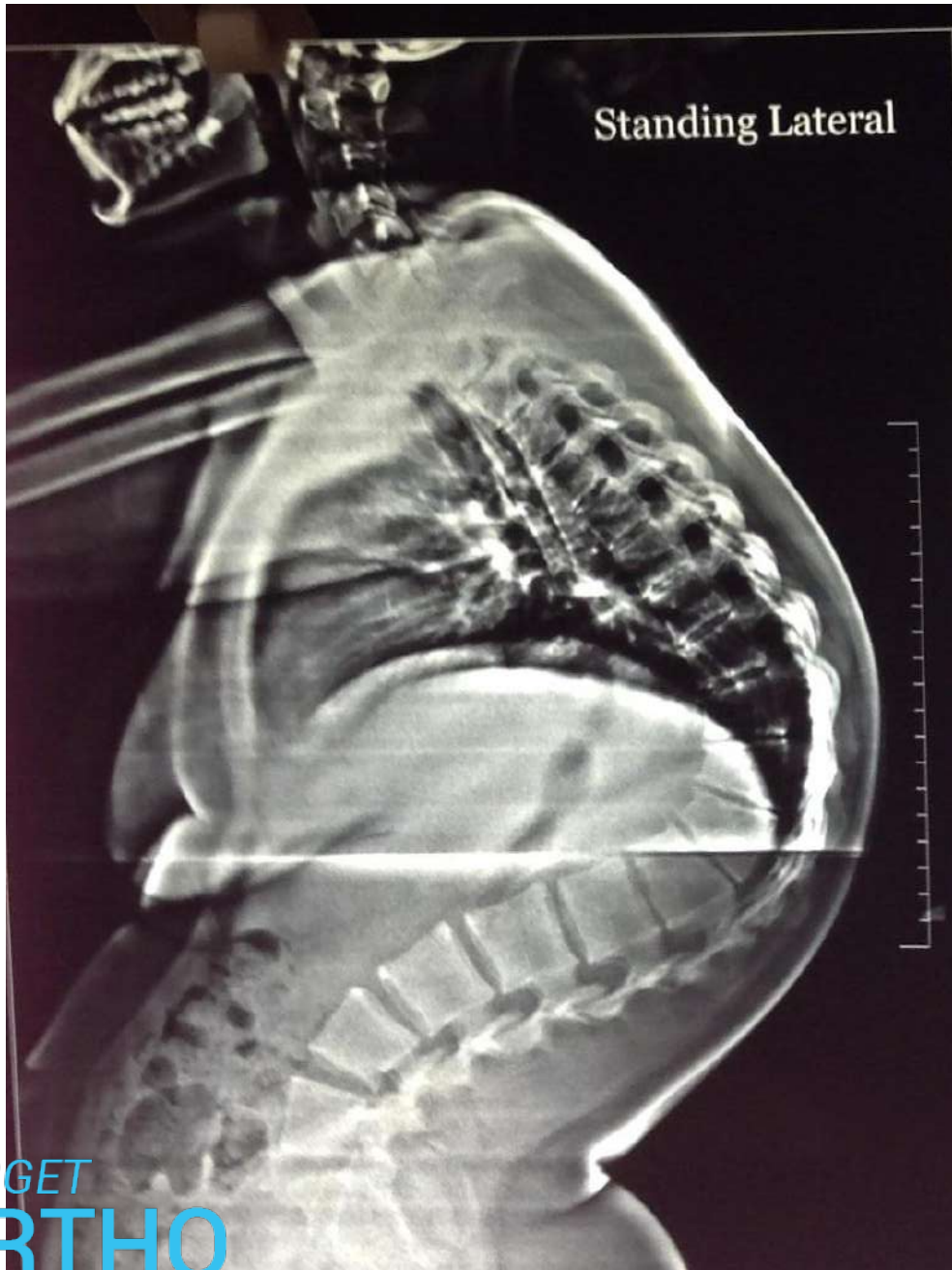
- Indications
 - Both sagittal and Coronal deformities can be addressed
 - Less extensive
- Correction : 10 degree per level
 - 1 degree per mm of bone resected

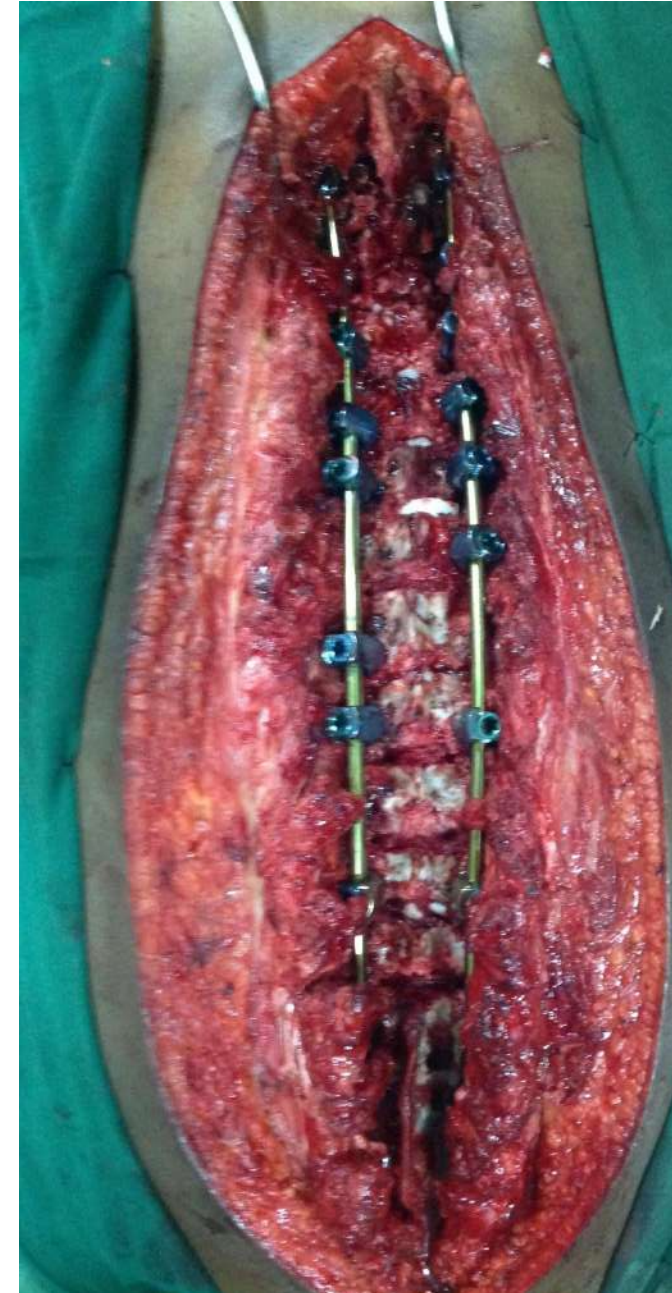
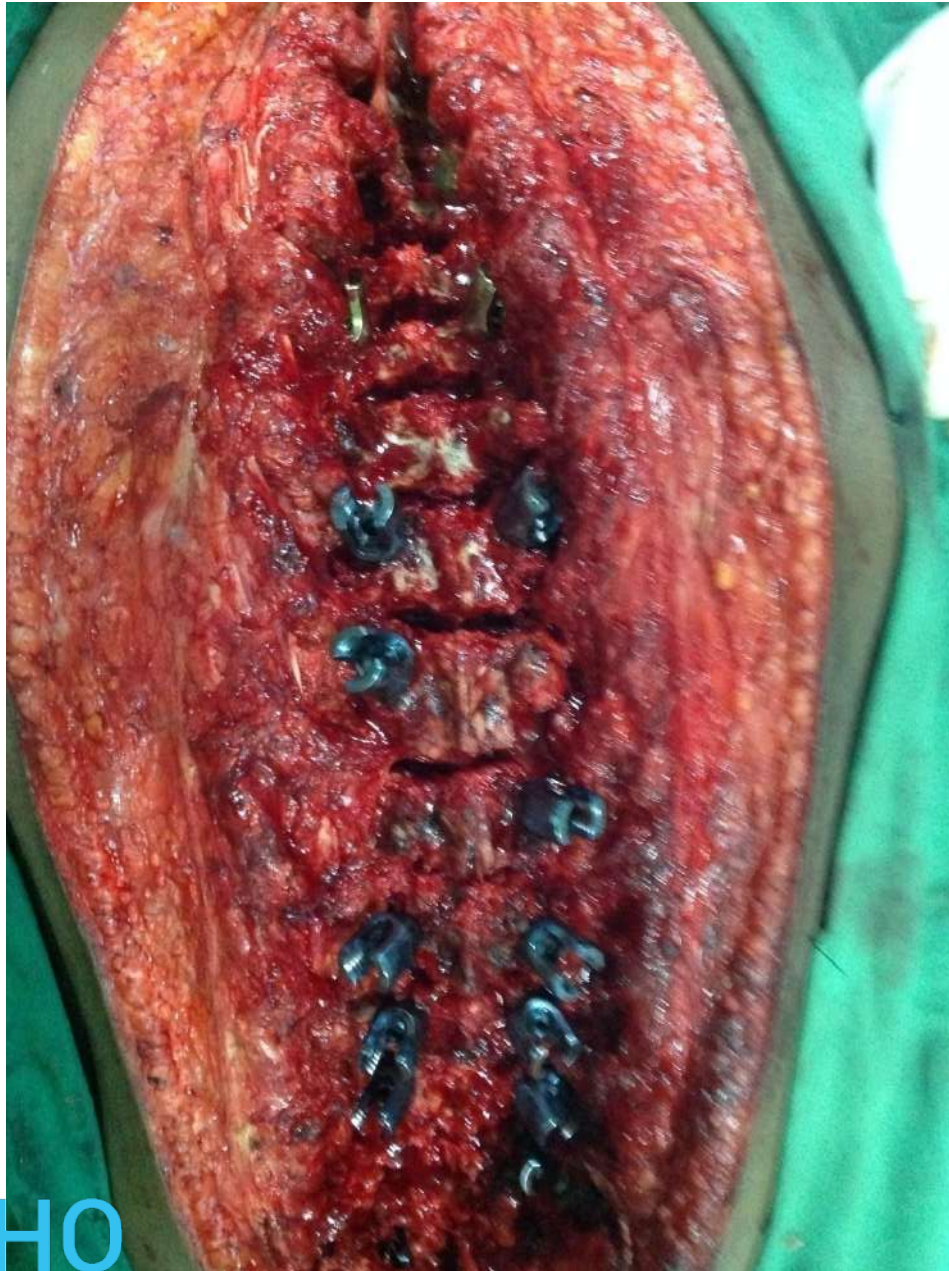
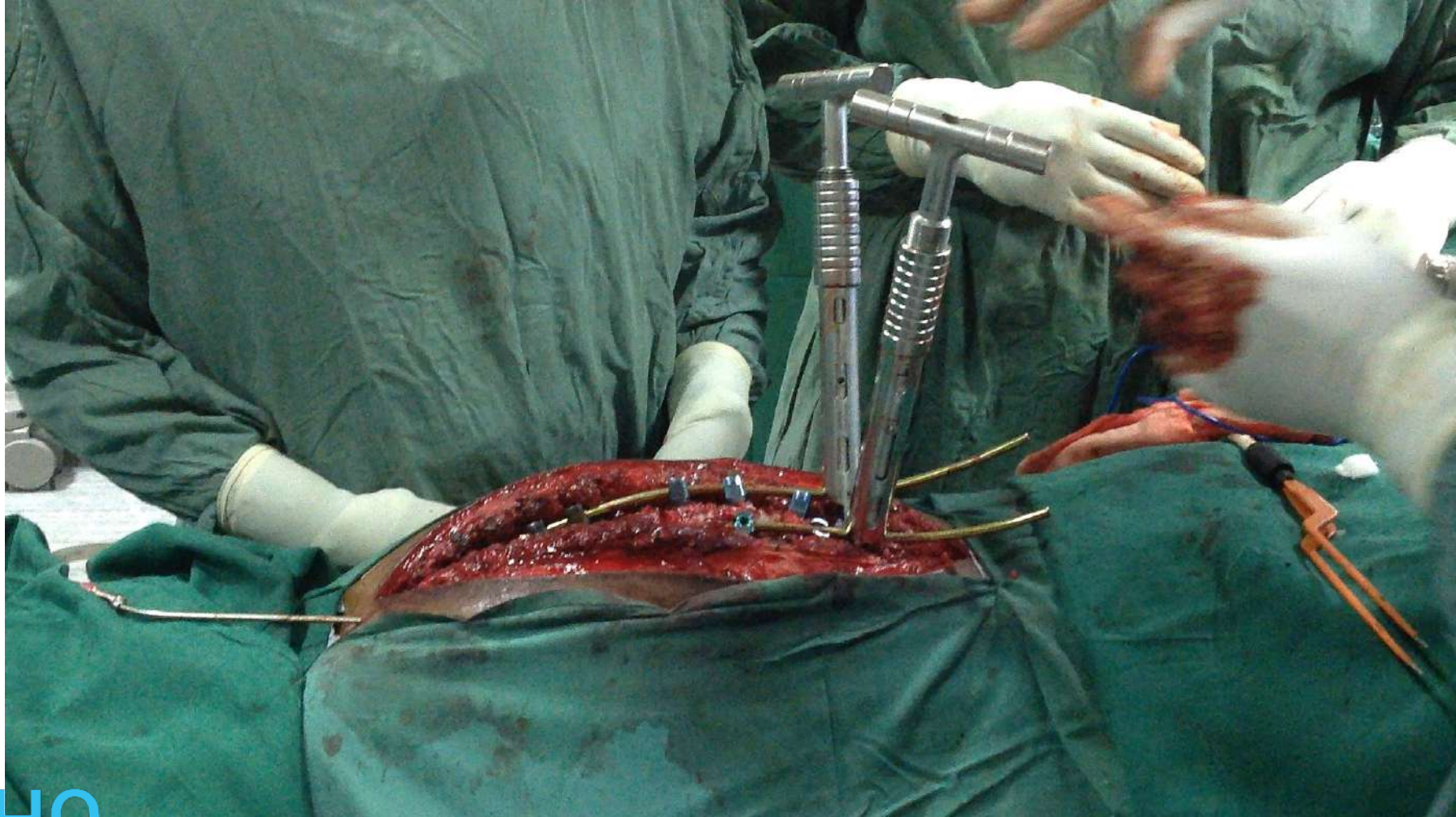
surgical treatment

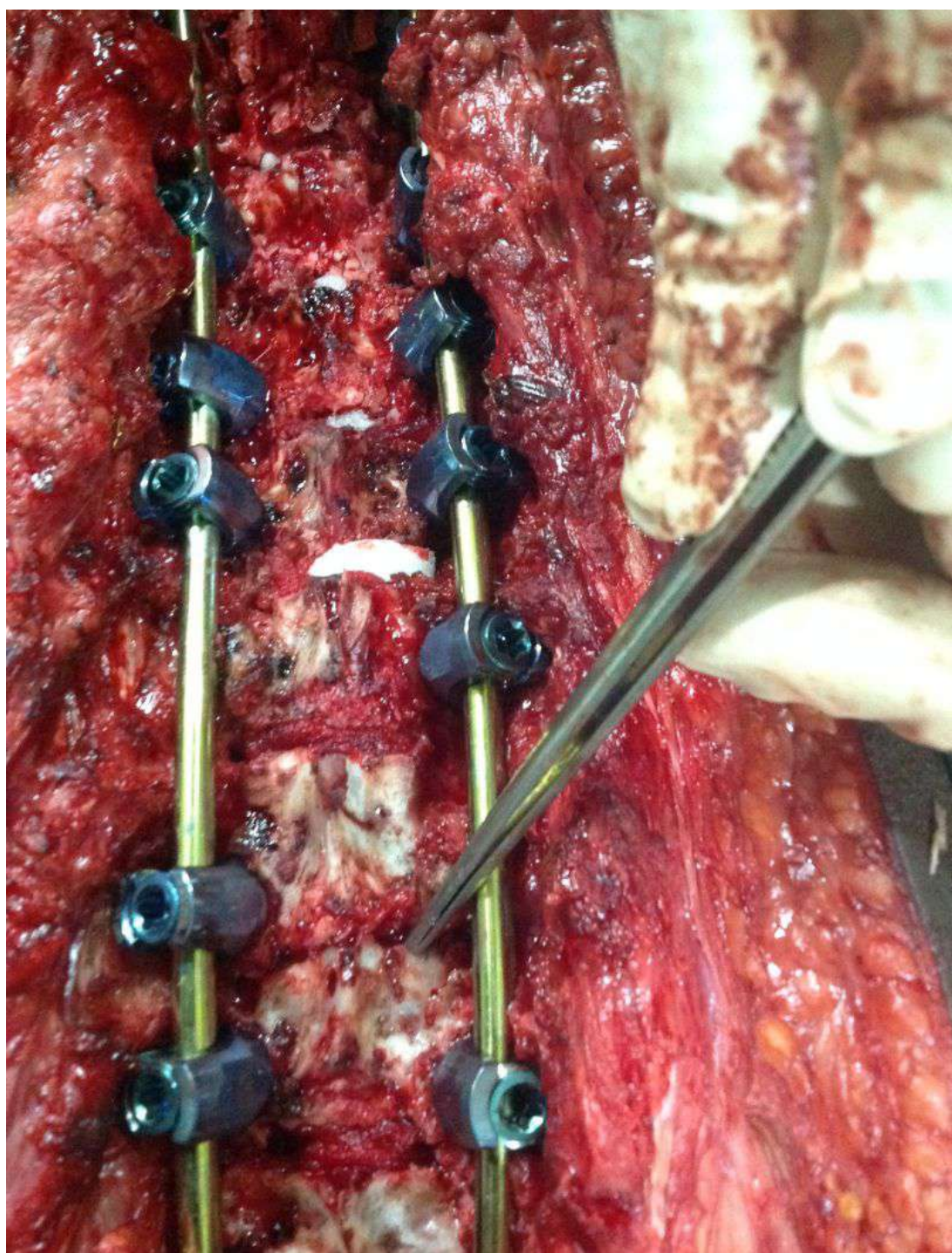


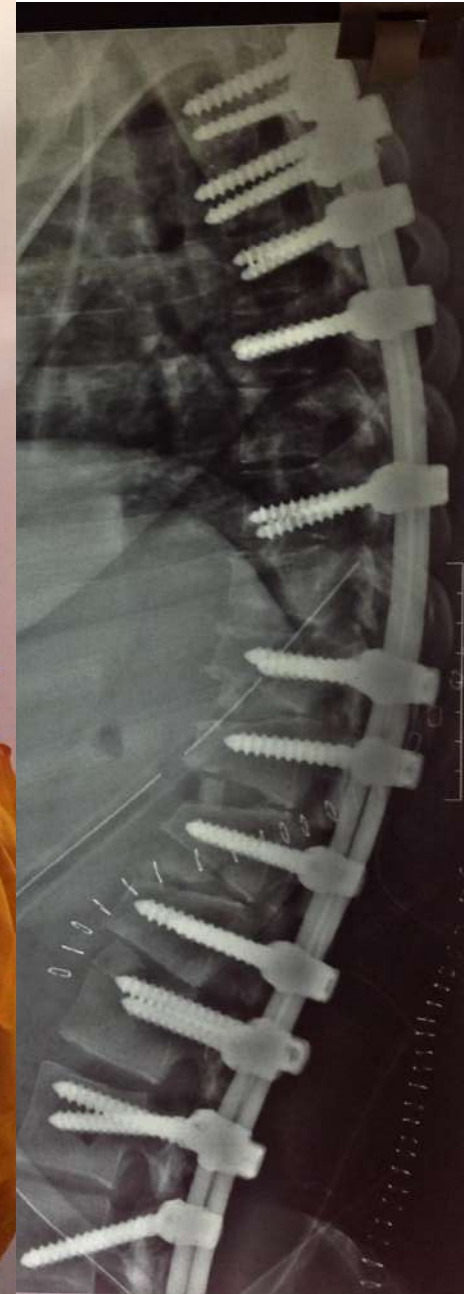
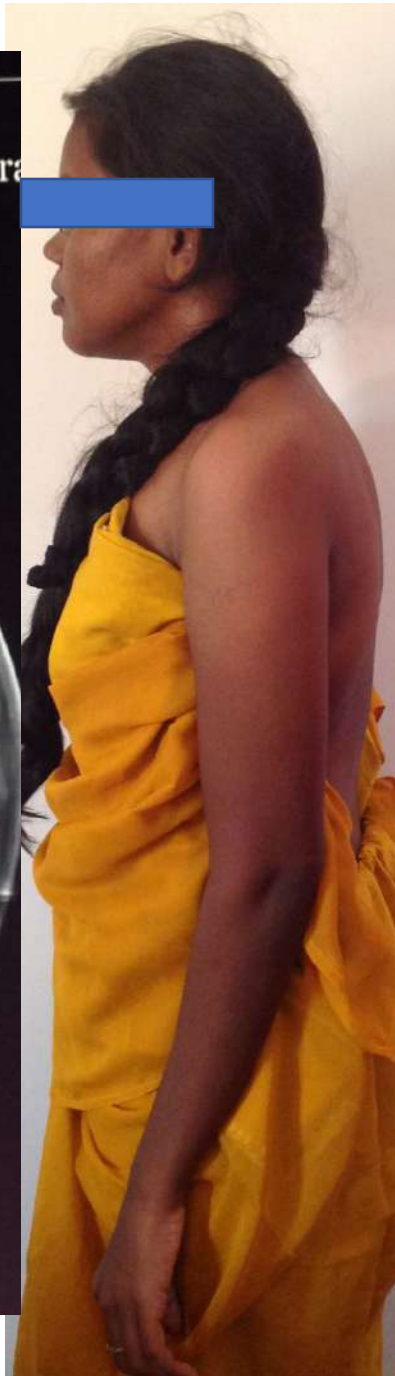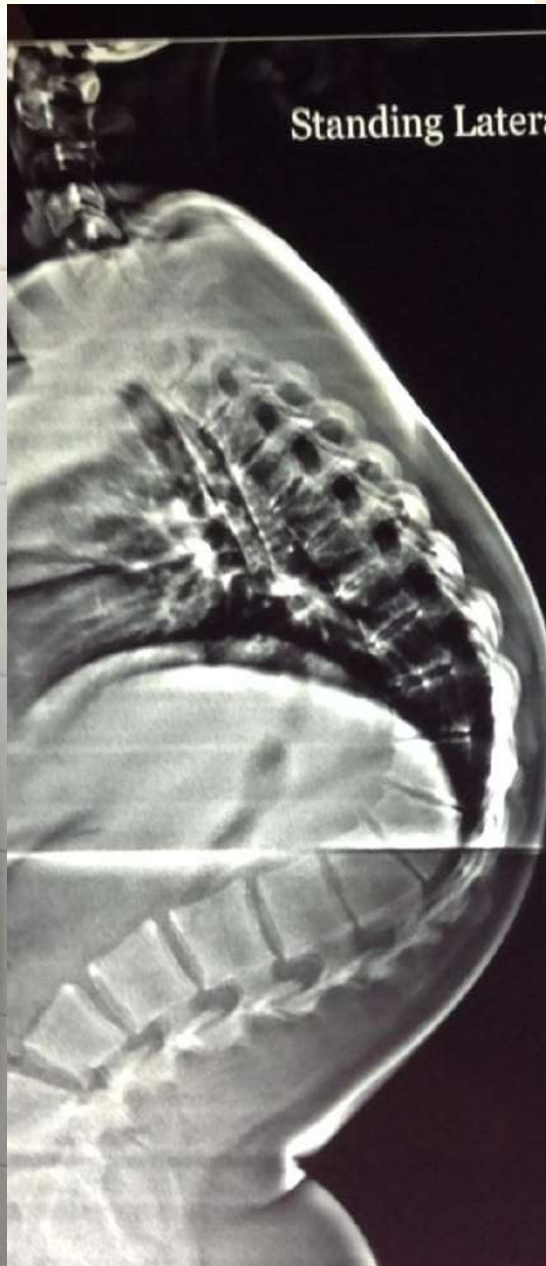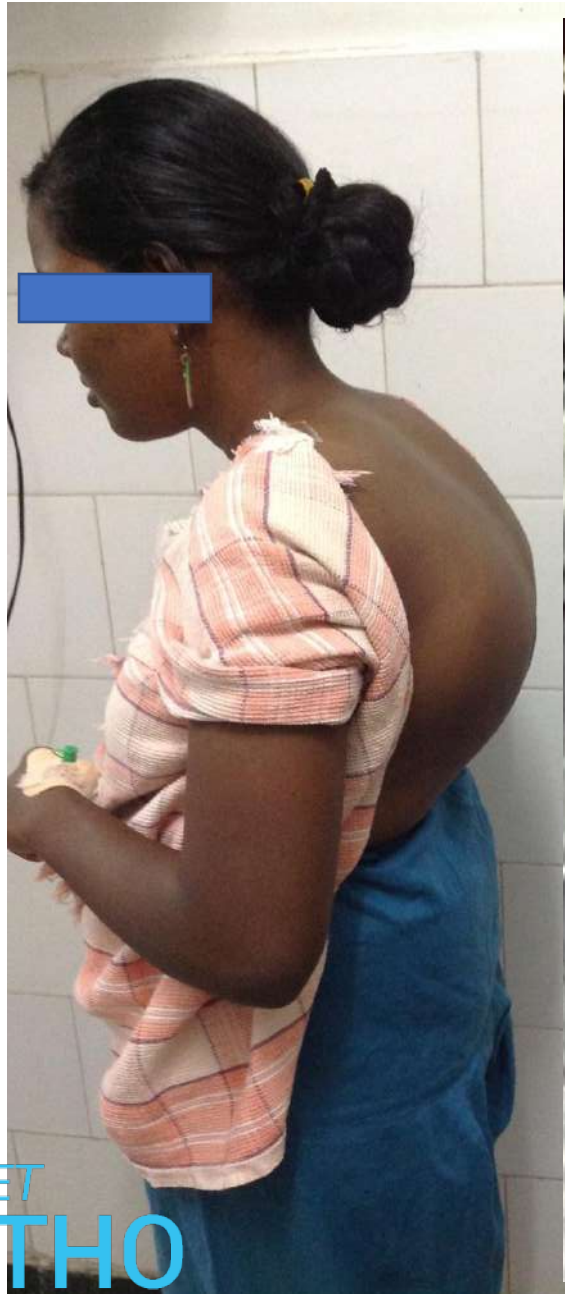Pontes osteotomy







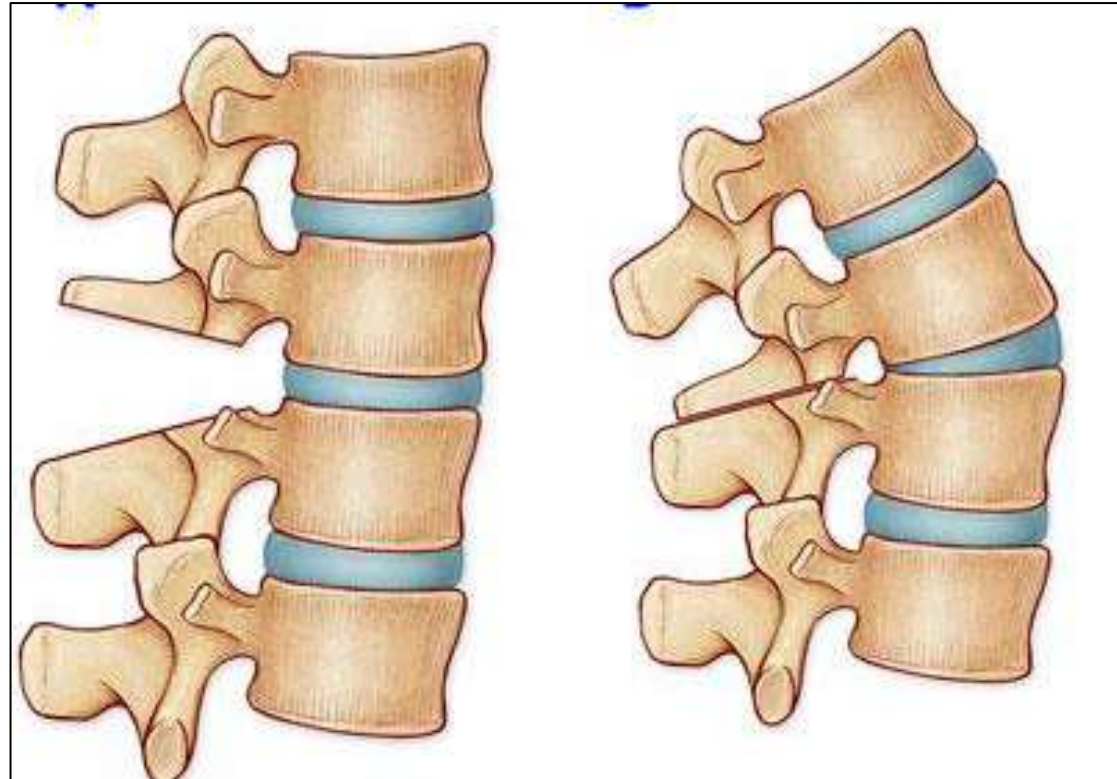




ateral 5061 Dr C S Vishnuprasath
S HOSPITAL - DR SYSTEM, SALEM

Smith Petersen Osteotomy

- Complications
 - Epidural bleeding
 - Neural impingement
 - Less correction

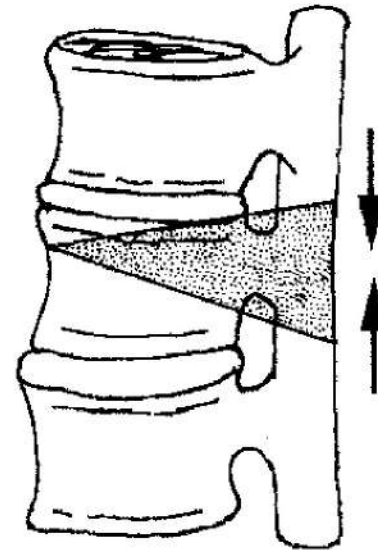


Pedicle Subtraction Osteotomy

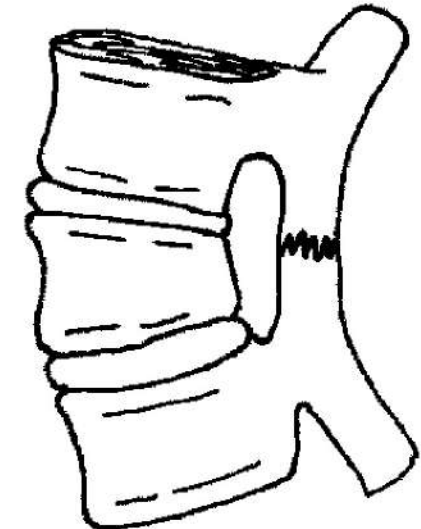
- Posterior elements and pedicles are removed
- De-cancellation technique or with osteotome
- Anterior cortex acts as hinge

Three Column Pedicle Subtraction Osteotomy

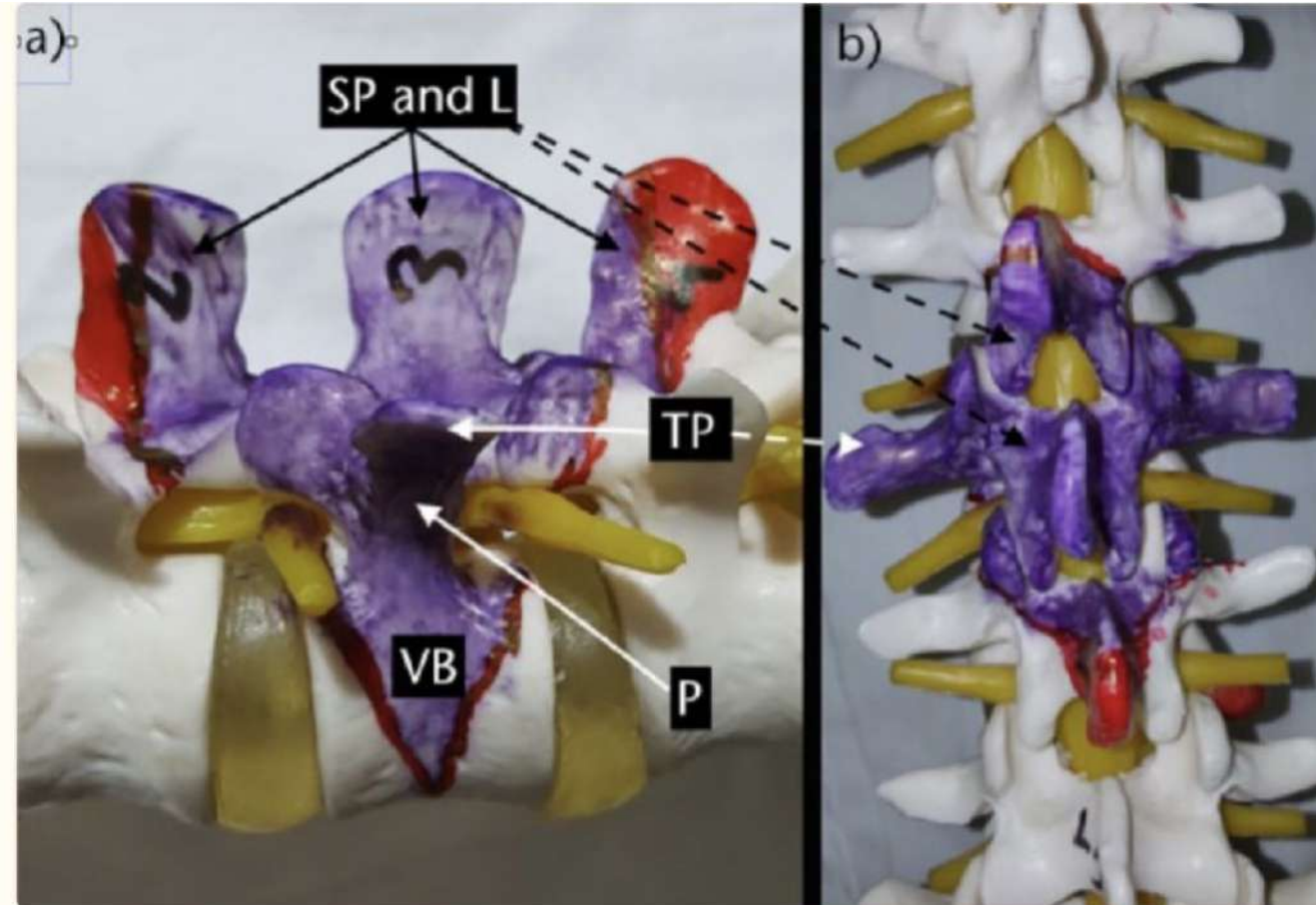
BEFORE



AFTER



Pedicle Subtraction Osteotomy

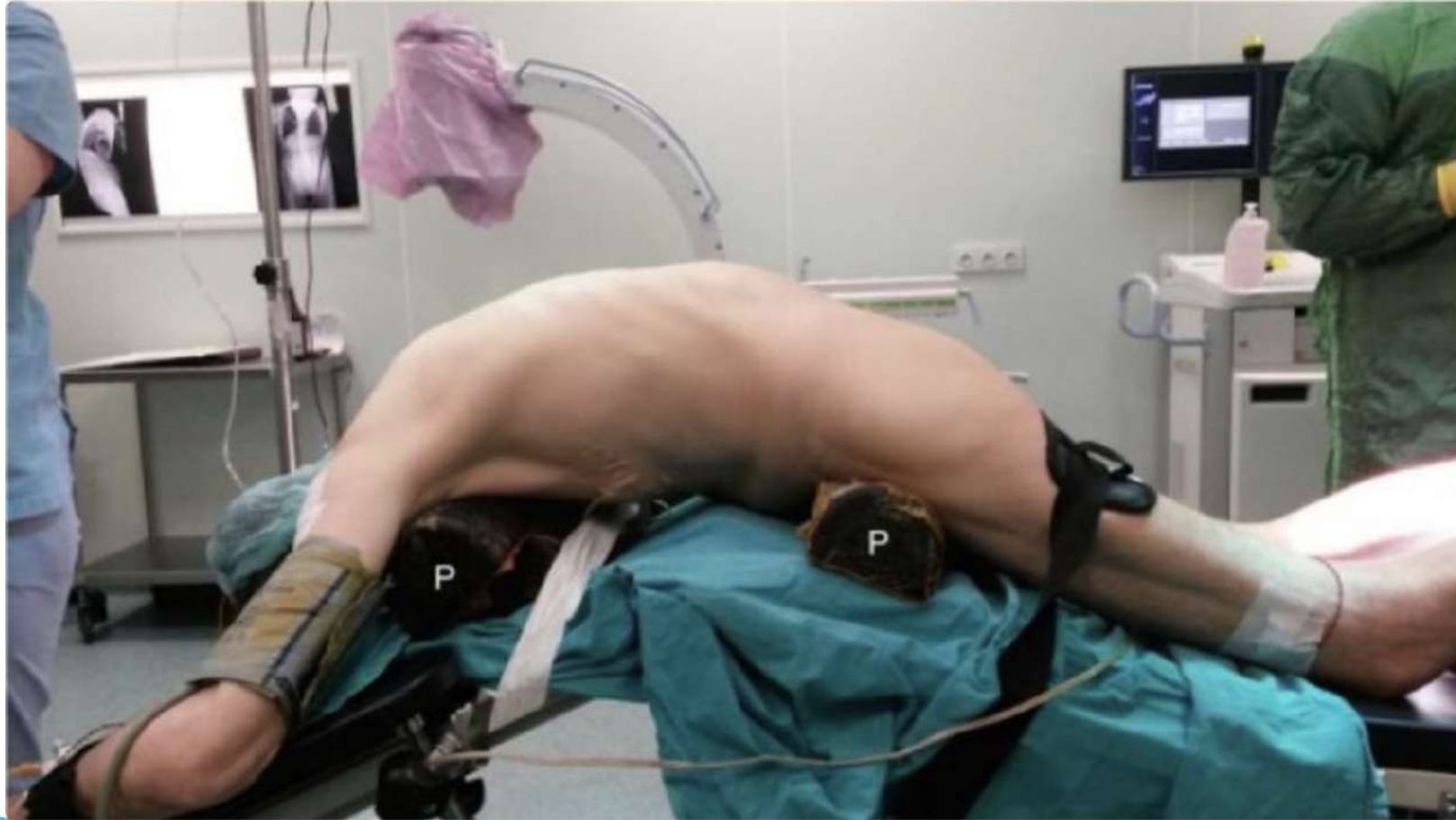

Pedicle Subtraction Osteotomy

- Indications
 - Sagittal and Coronal plane deformity
 - Previously fused spine
 - Single level : 30-40 deg correction

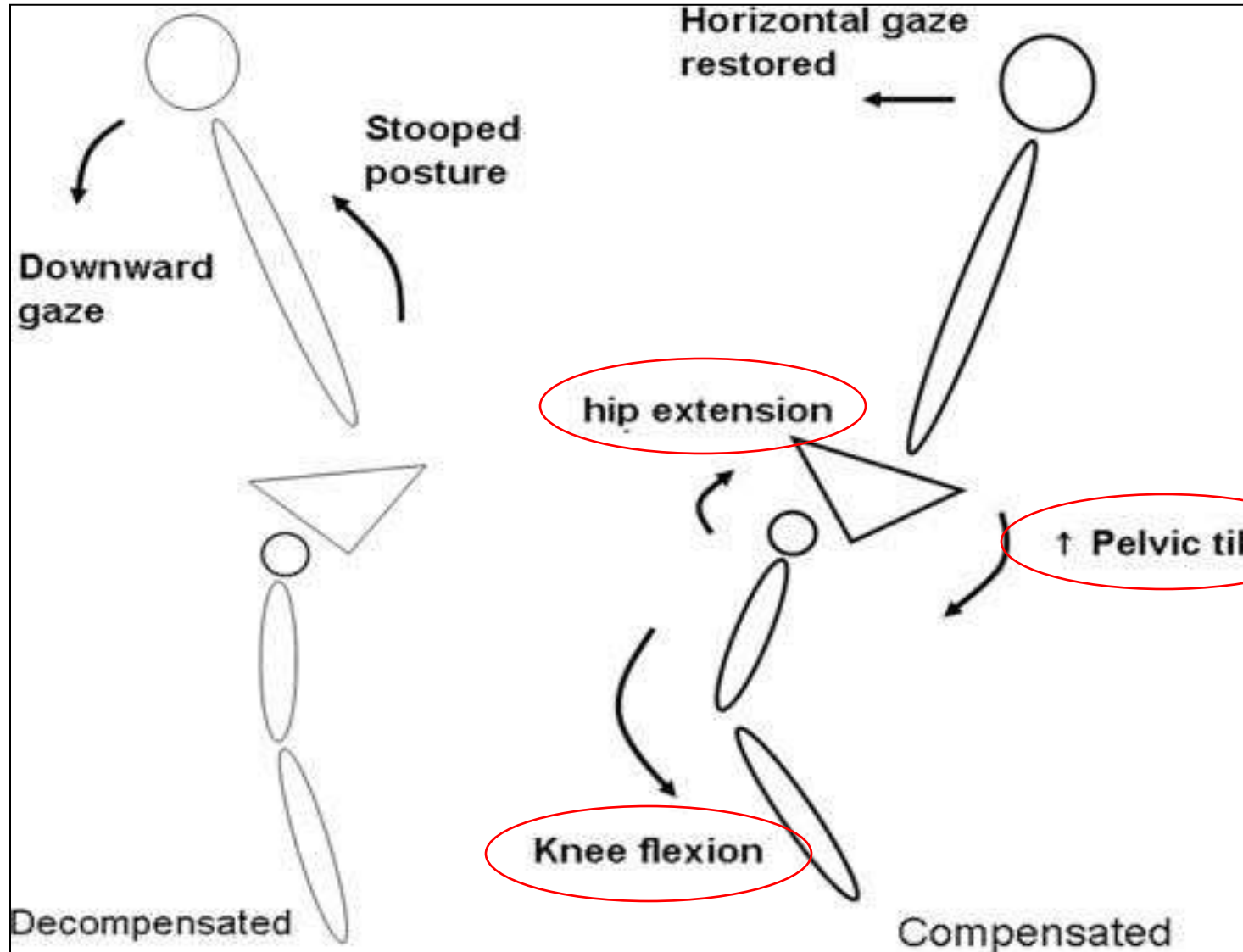
- Limitation
 - Kyphosis > 40

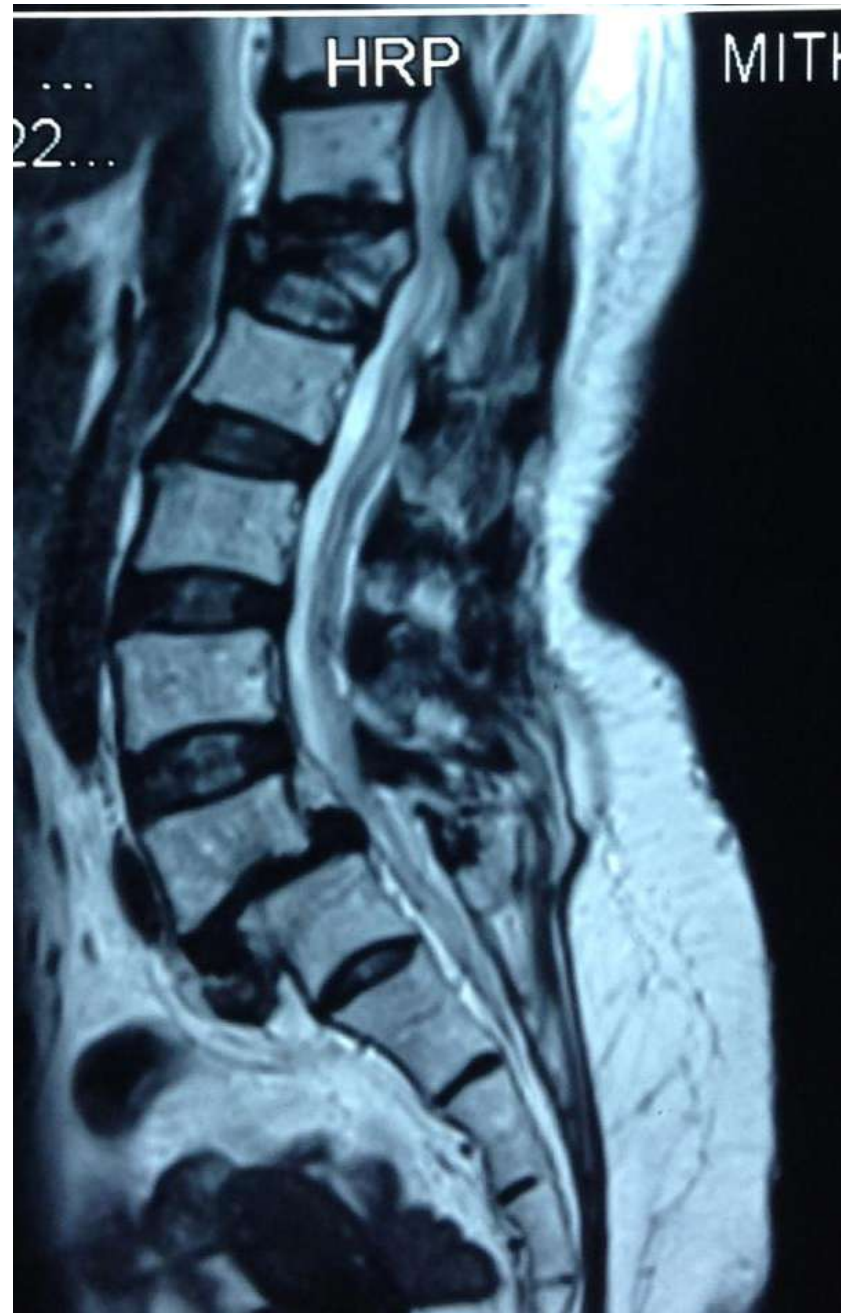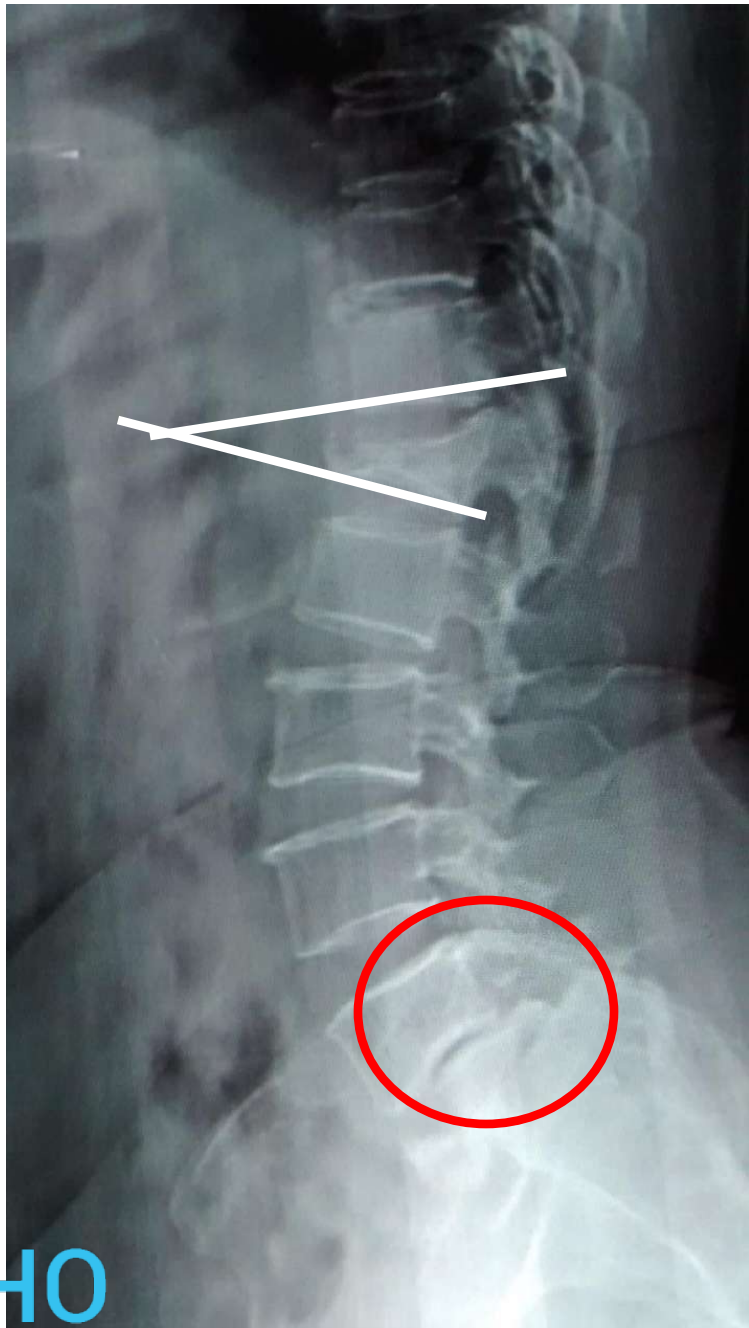Pedicle Subtraction Osteotomy



Balancing mechanism

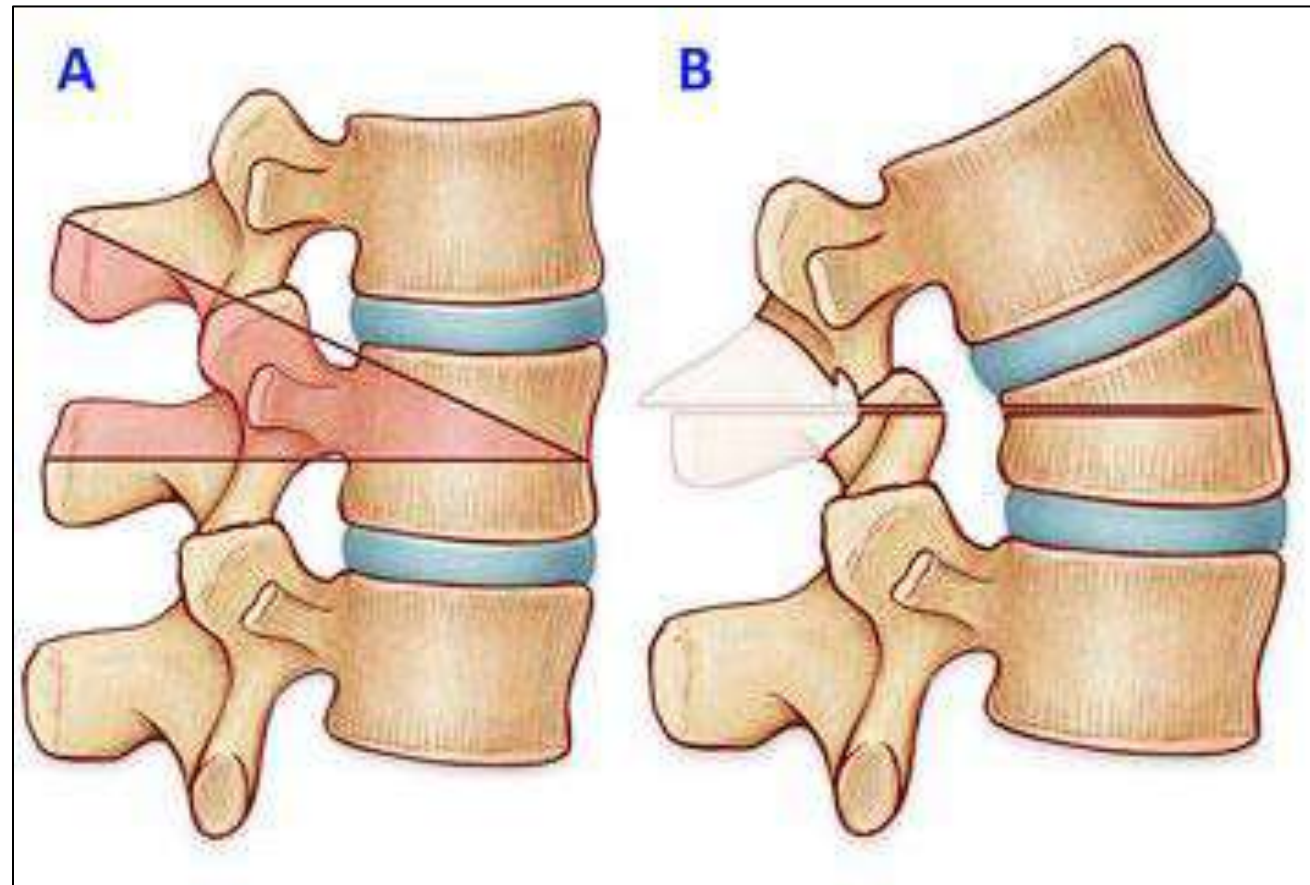
Hip and knee



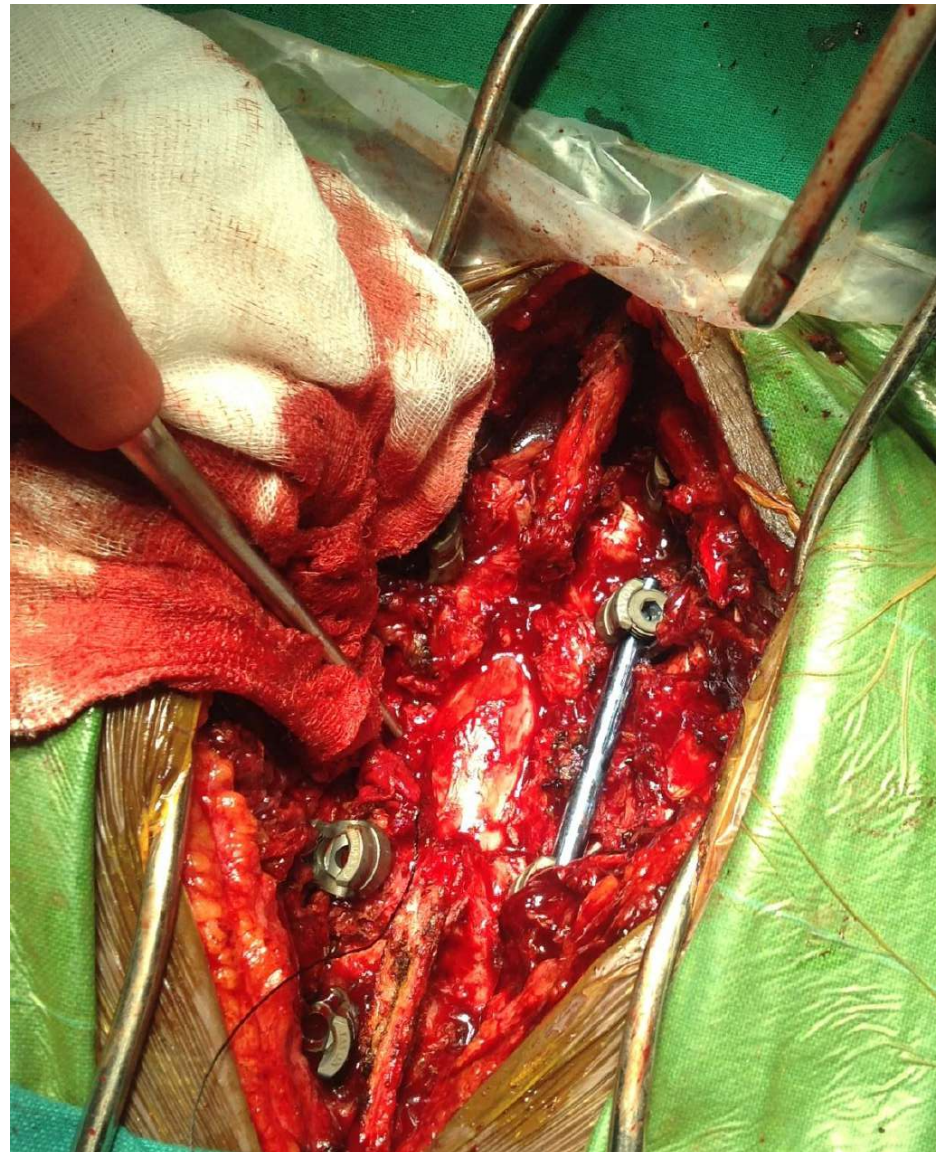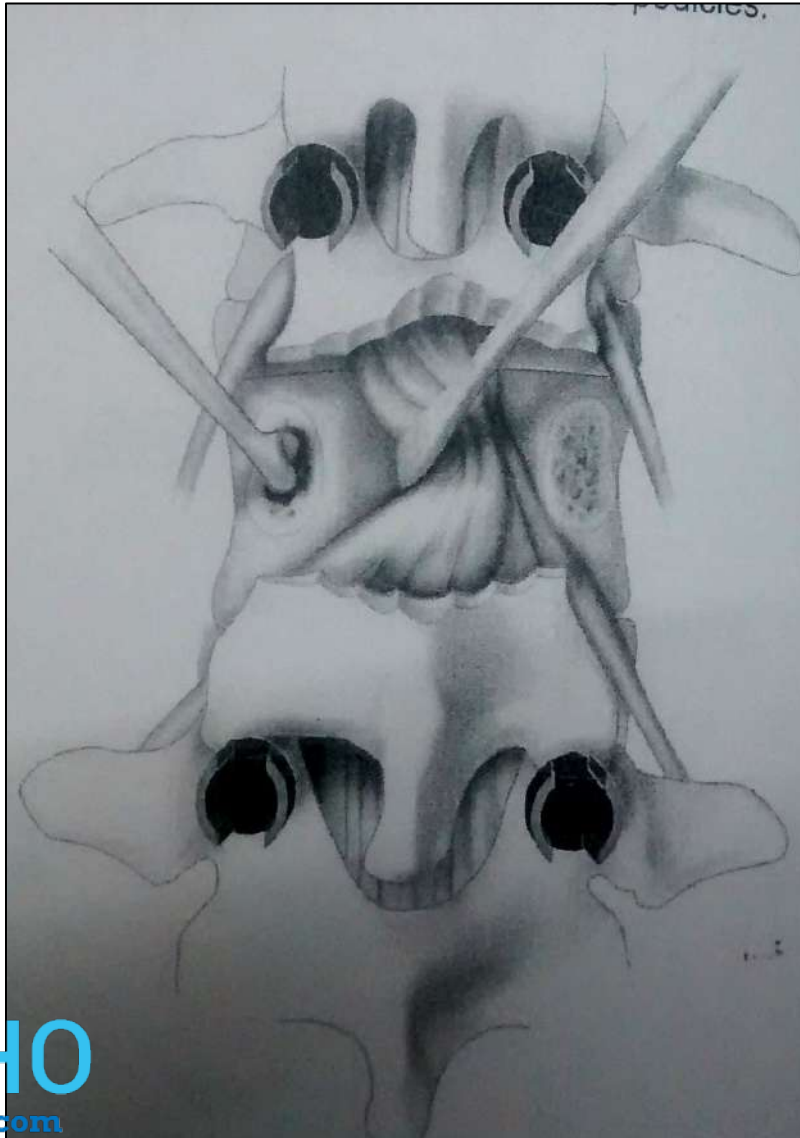




Pedicle subtraction osteotomy

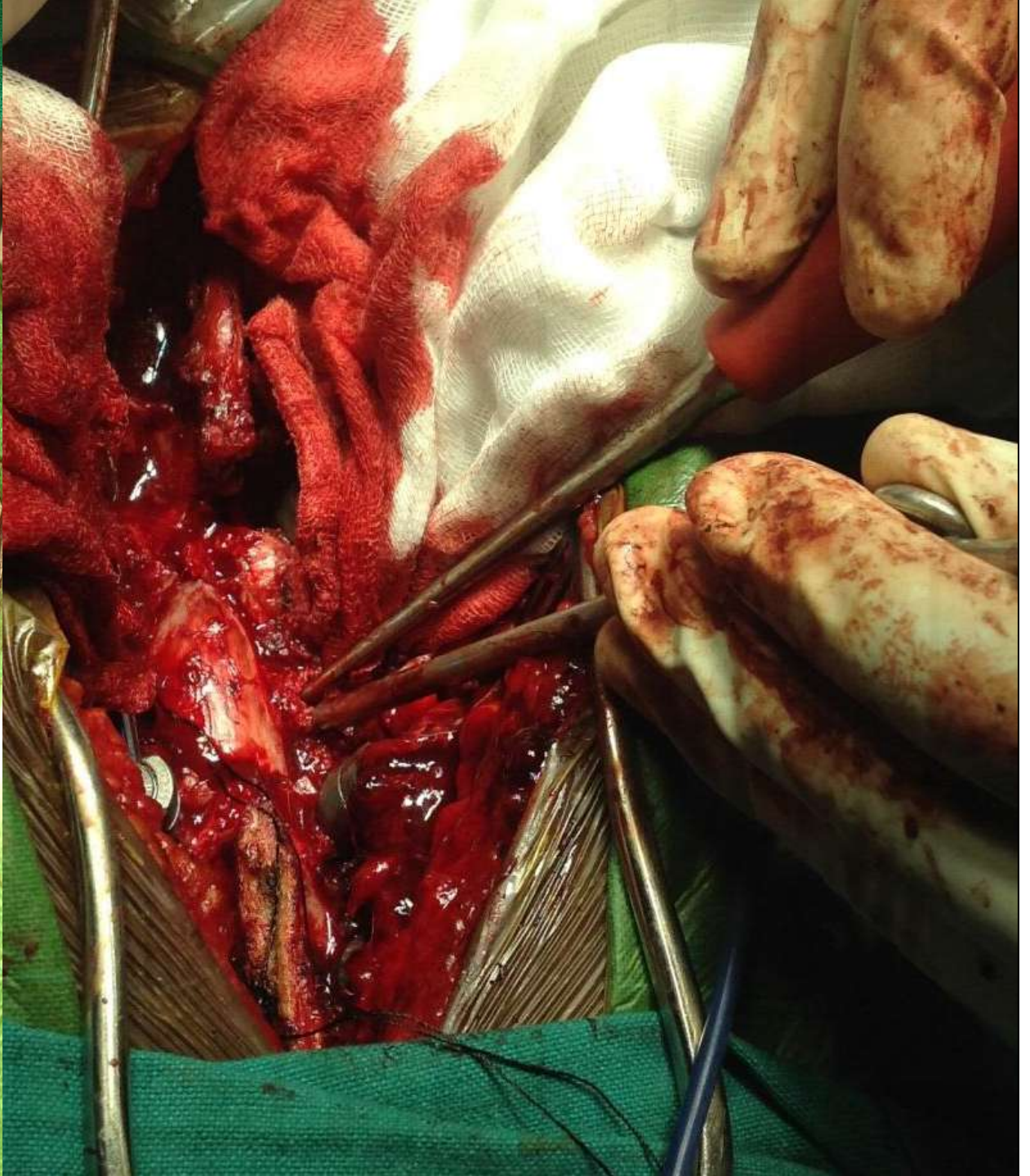
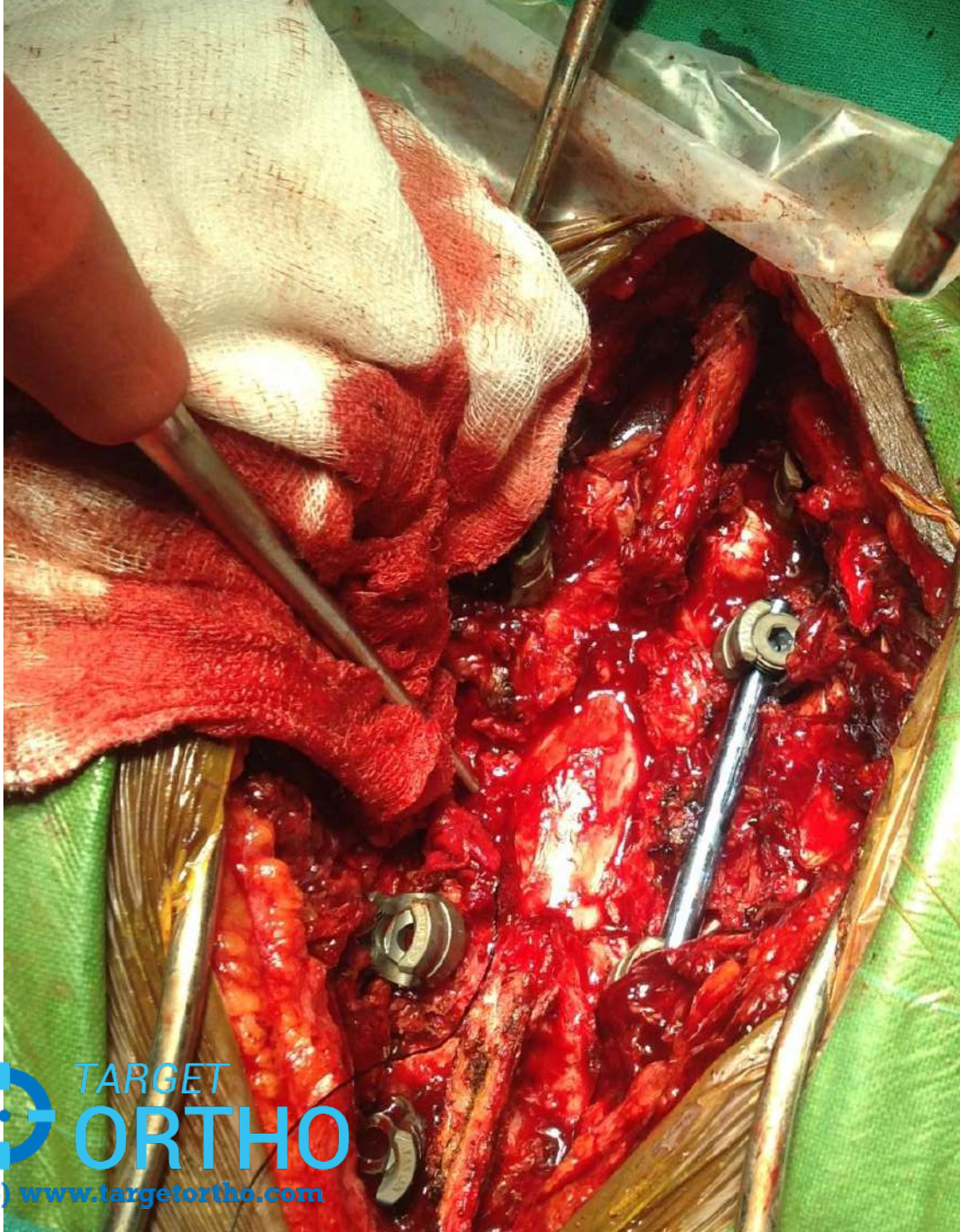


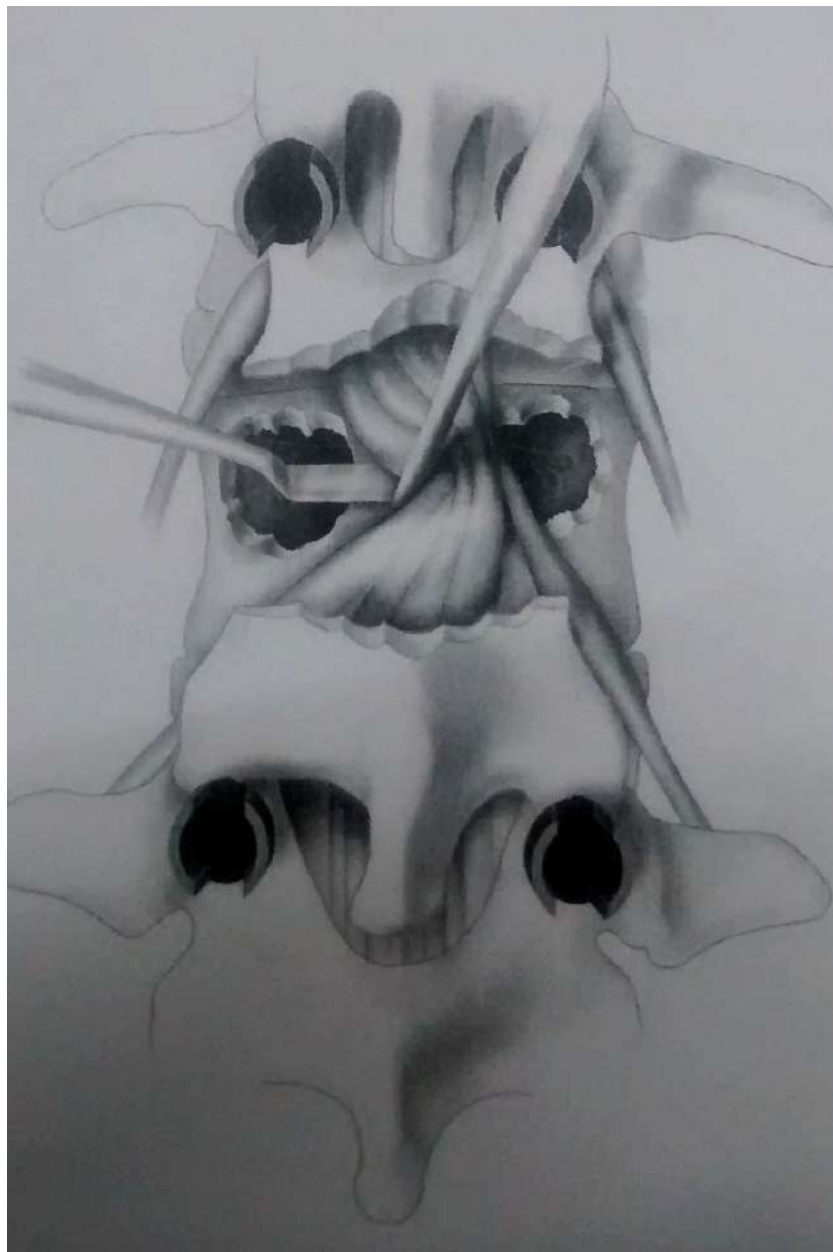Pedicle subtraction osteotomy

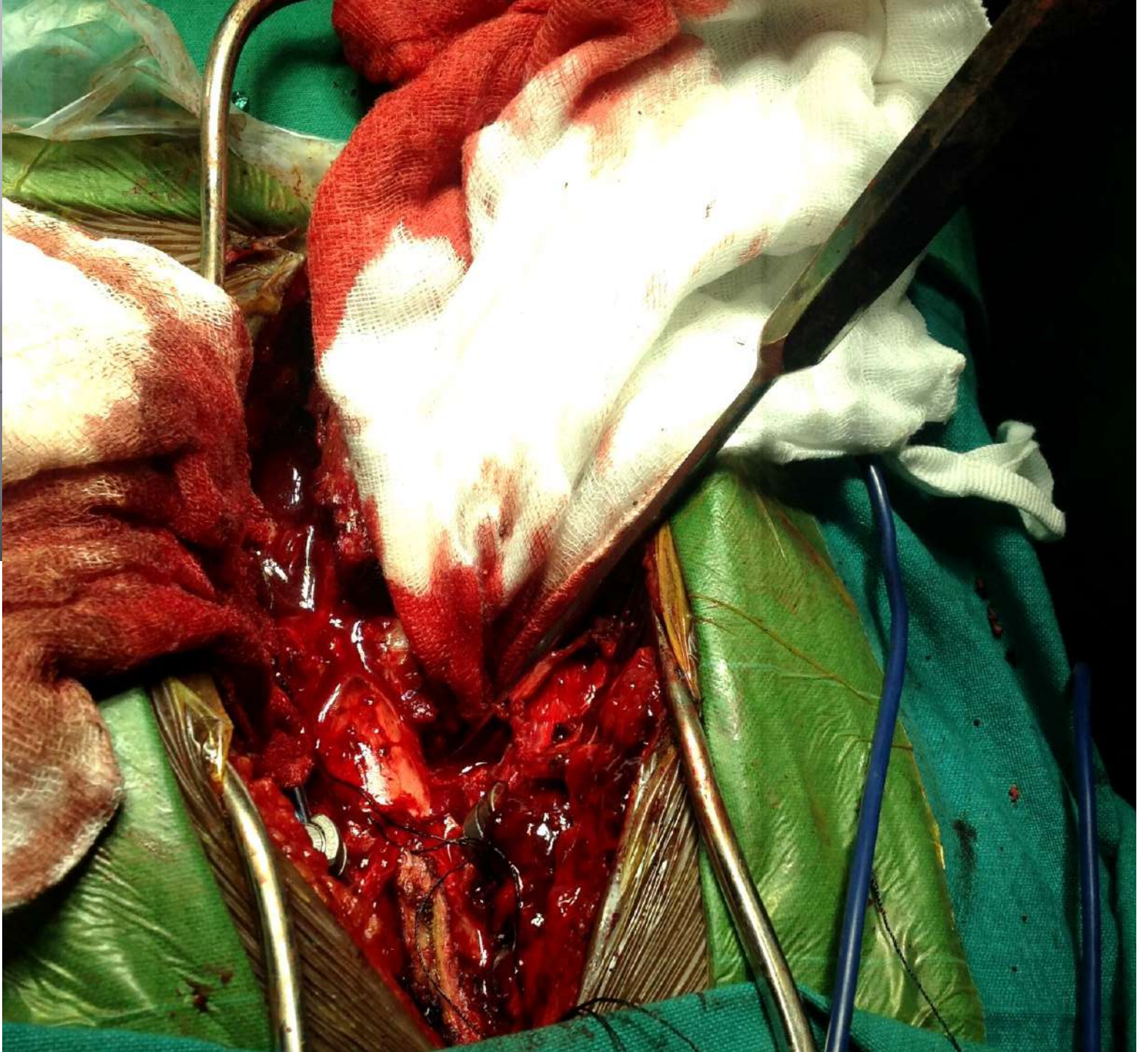
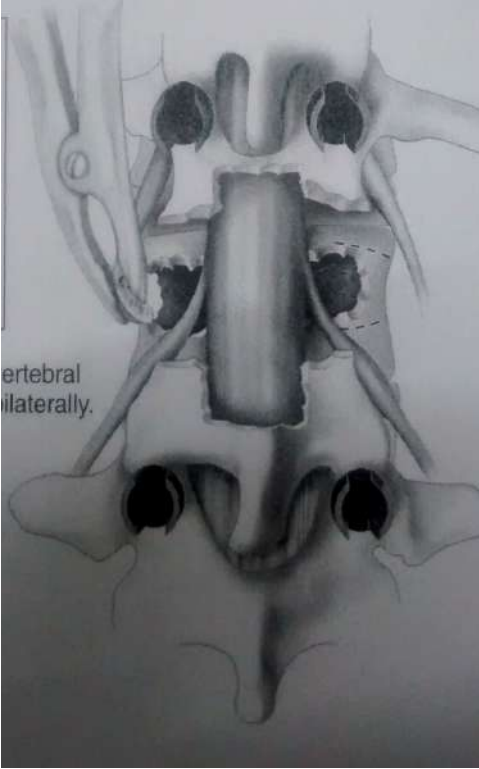


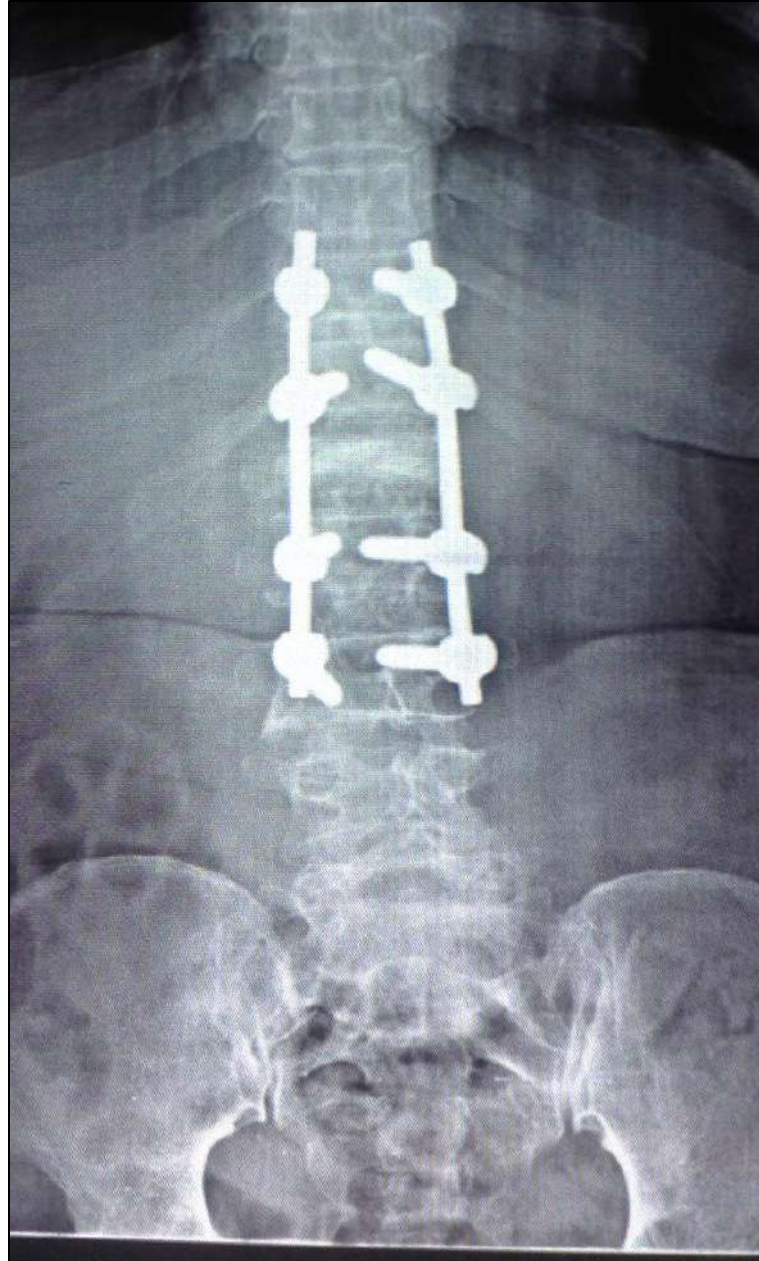
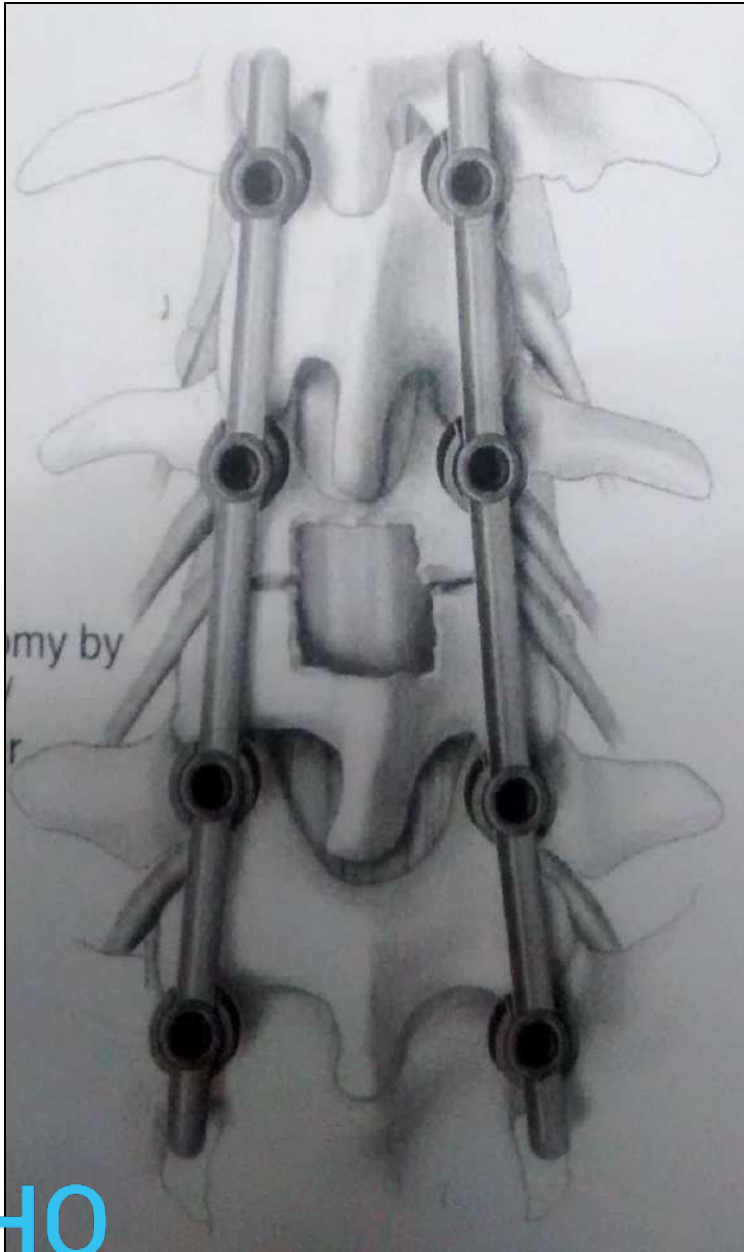
ate the pedicles

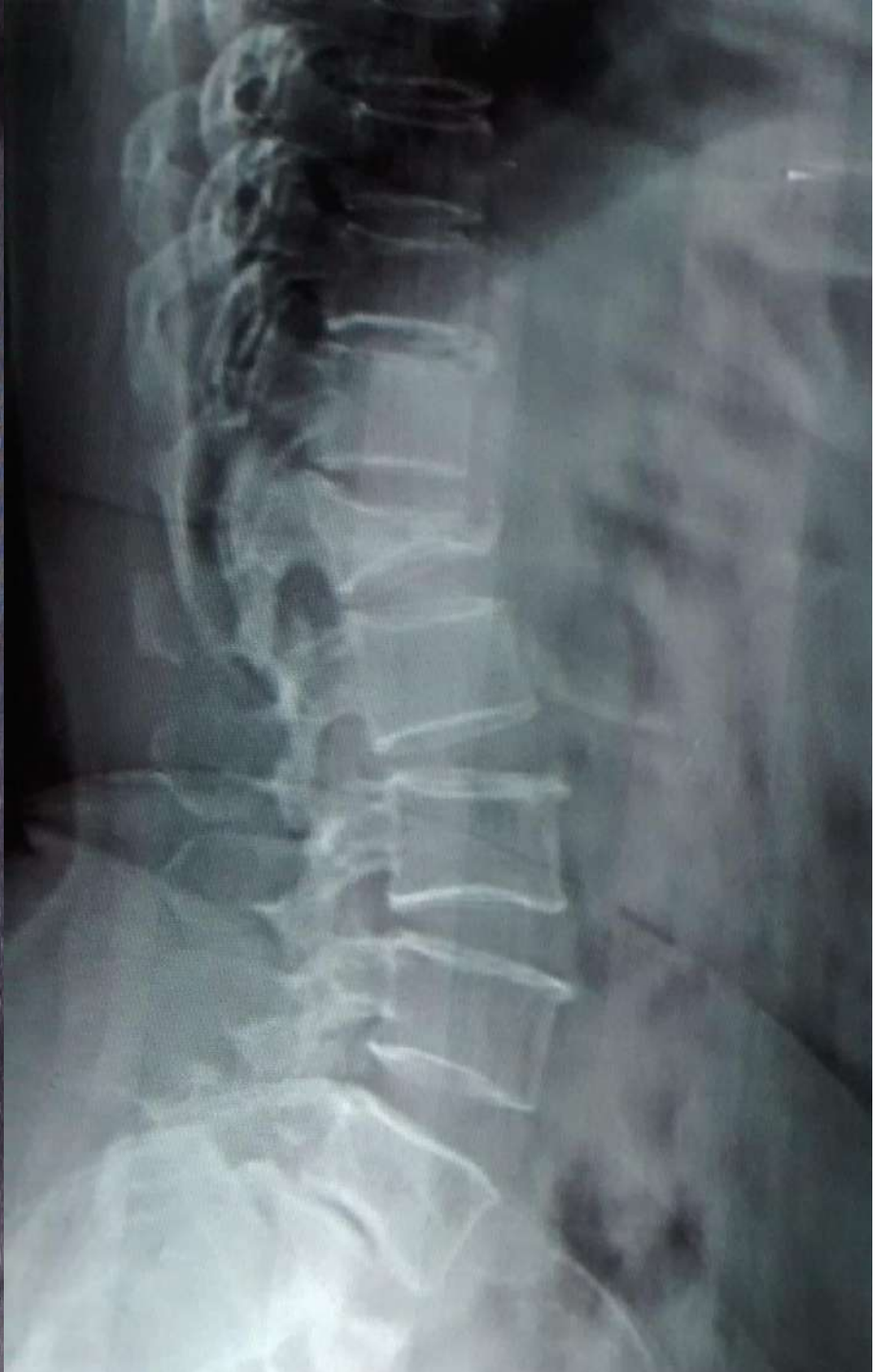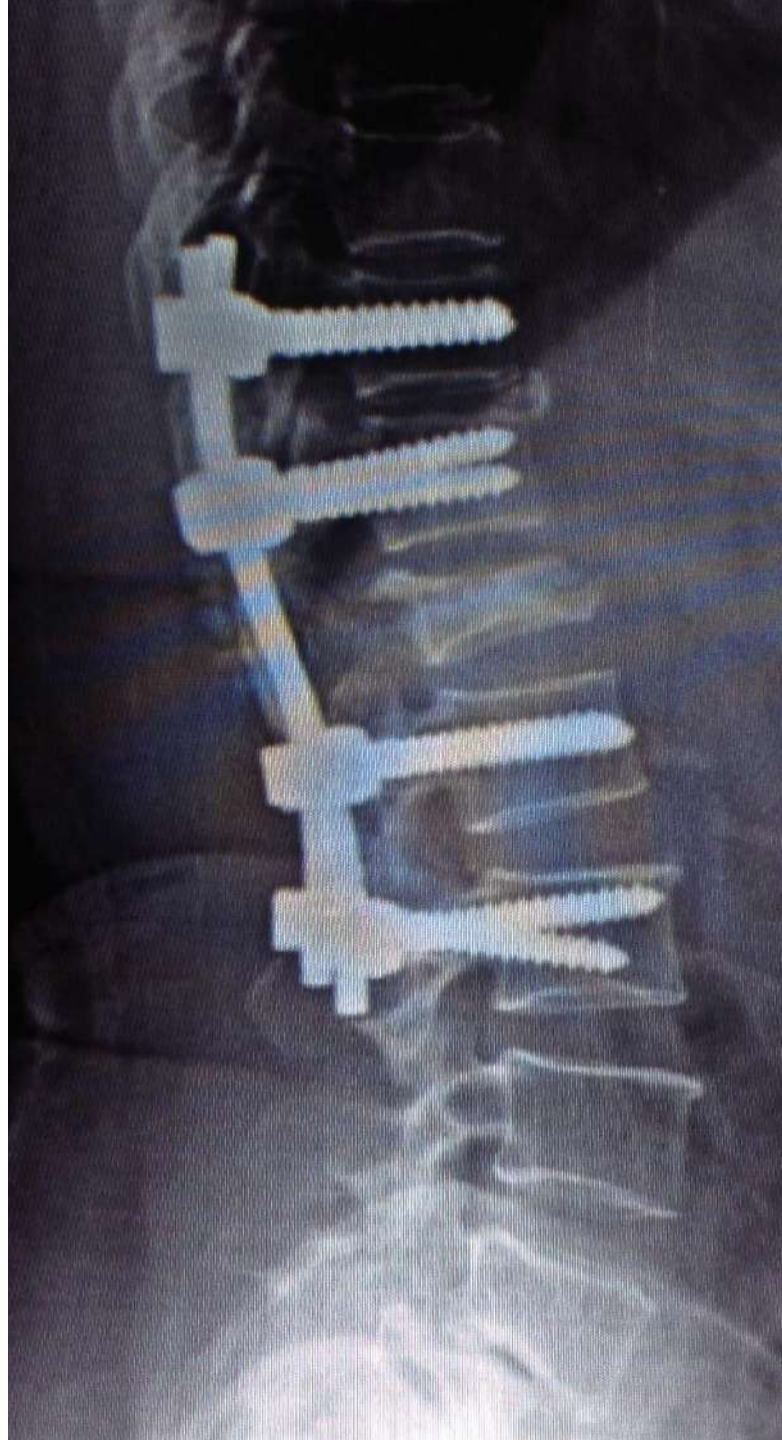












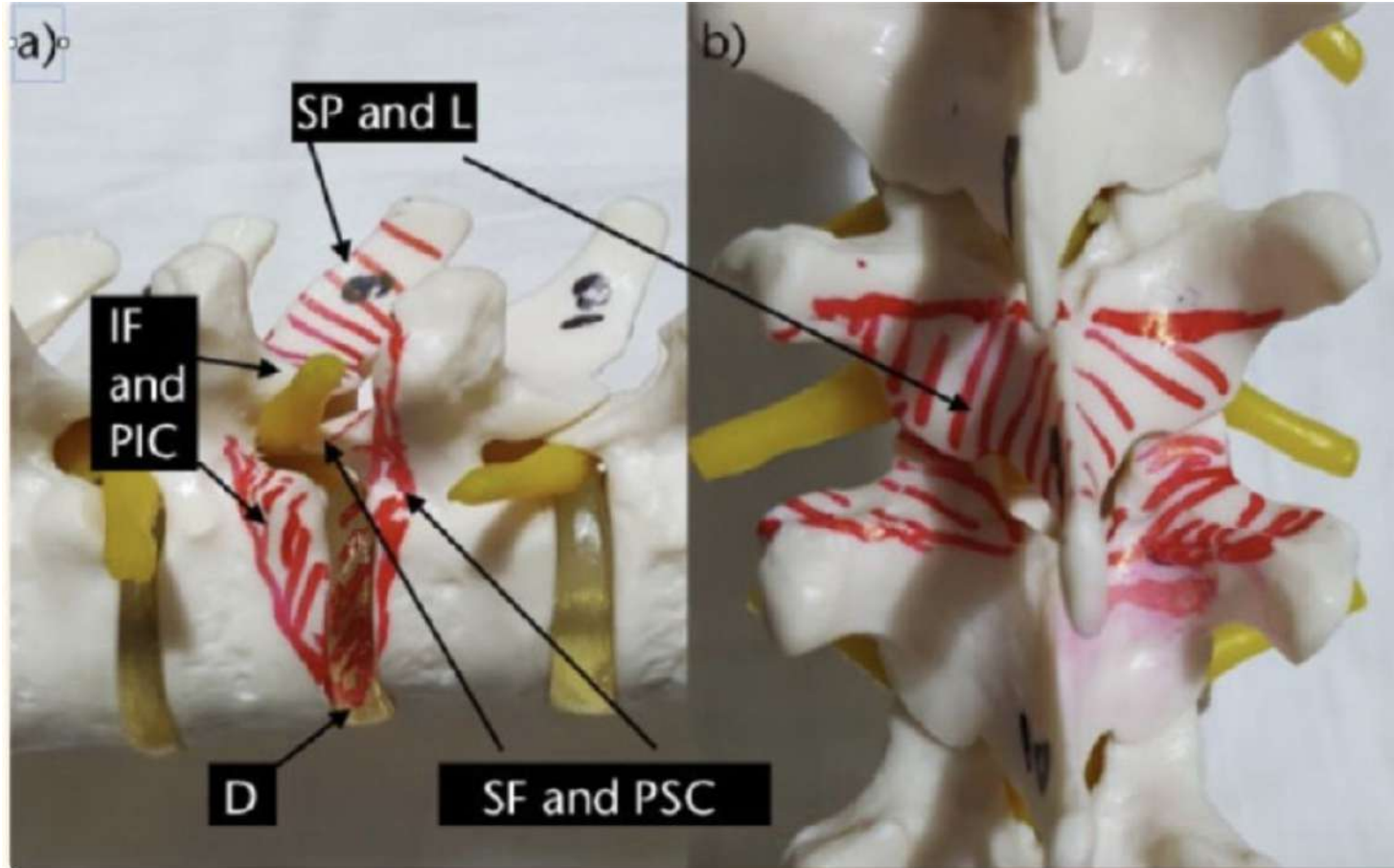
Pedicle Subtraction Osteotomy

- Pitfalls
 - Blood Loss : upto 2L
 - Transient Neurodeficit :
 - Radiculopathy
 - Single root weakness
 - Cauda Equina
 - Pseudoarthrosis : TL and LS junction
 - Infection : 4-7%

Bone Disc Bone Osteotomy

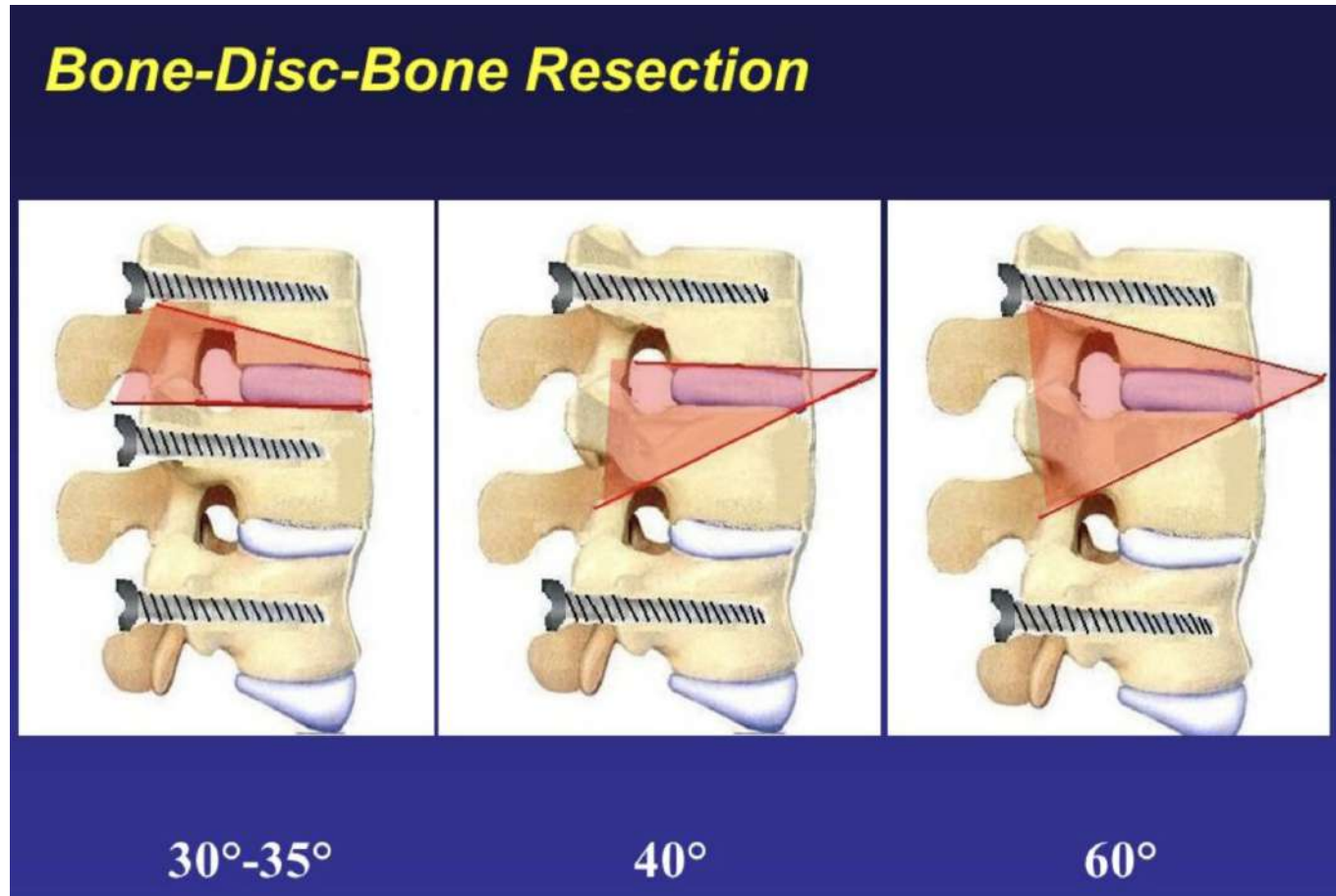
- BDBO is an osteotomy done both above and below a disc level and the resection includes the disc with its adjacent end-plate(s).
- correction rates : 35° to 60°

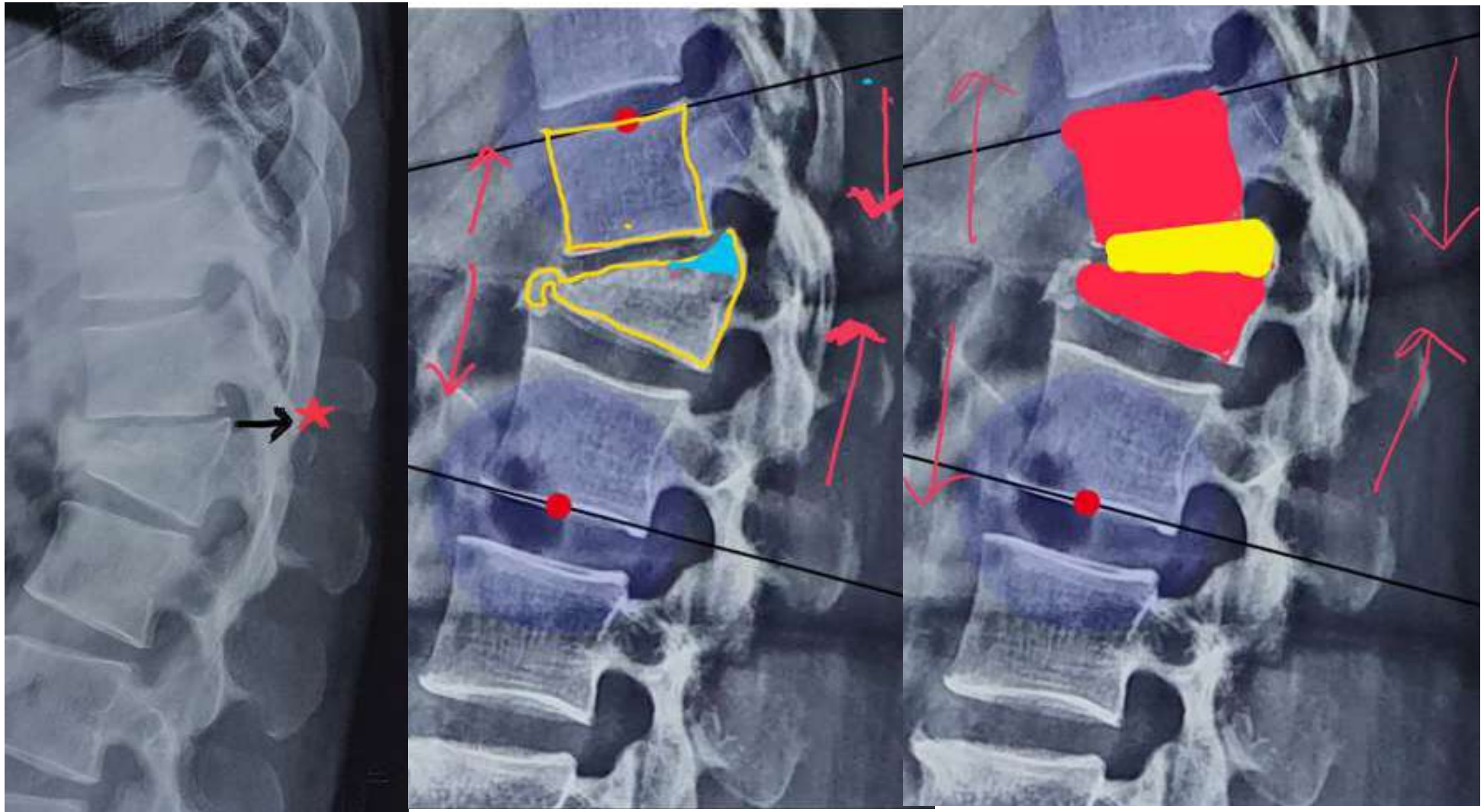
Bone Disc Bone Osteotomy

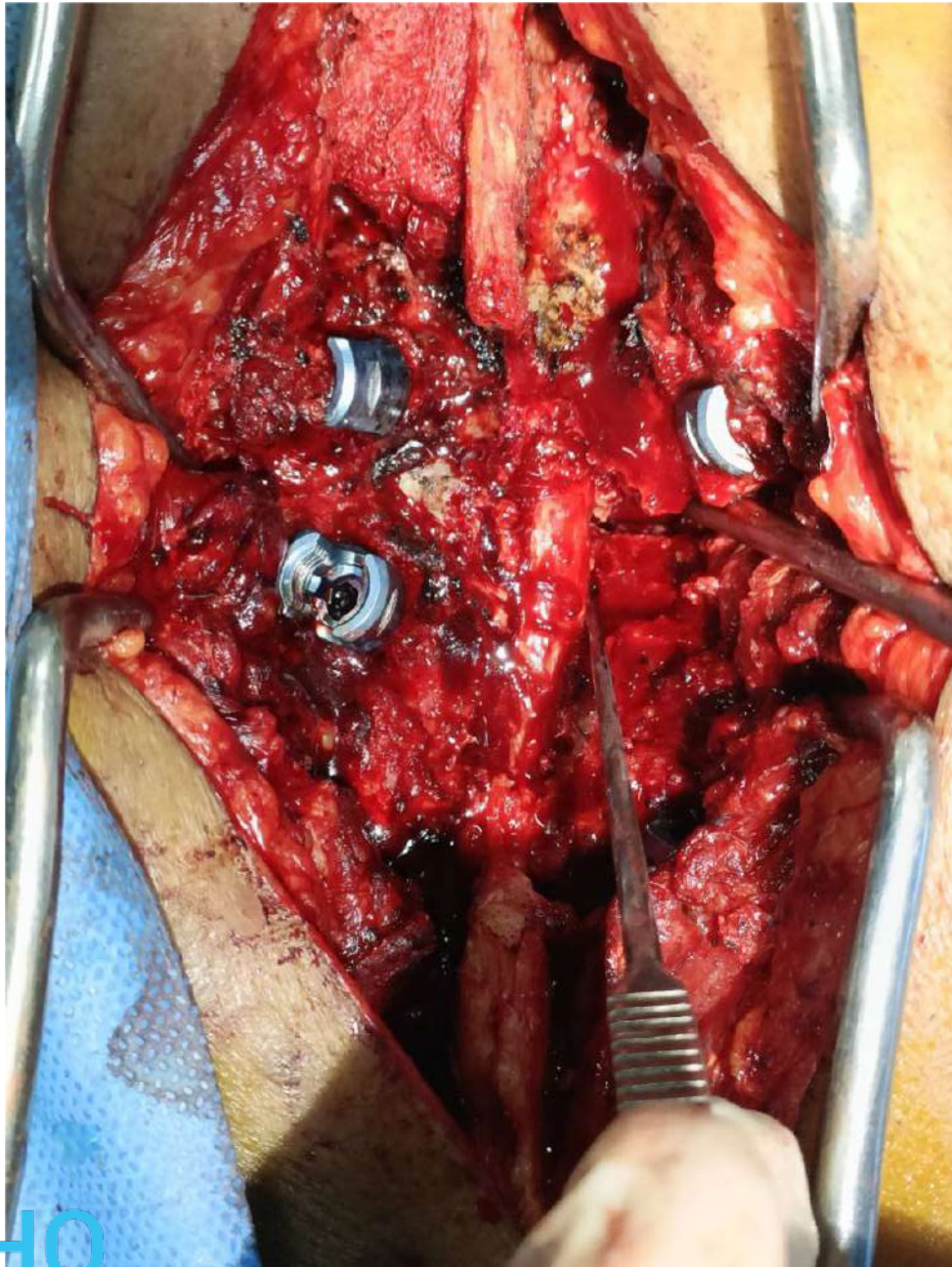


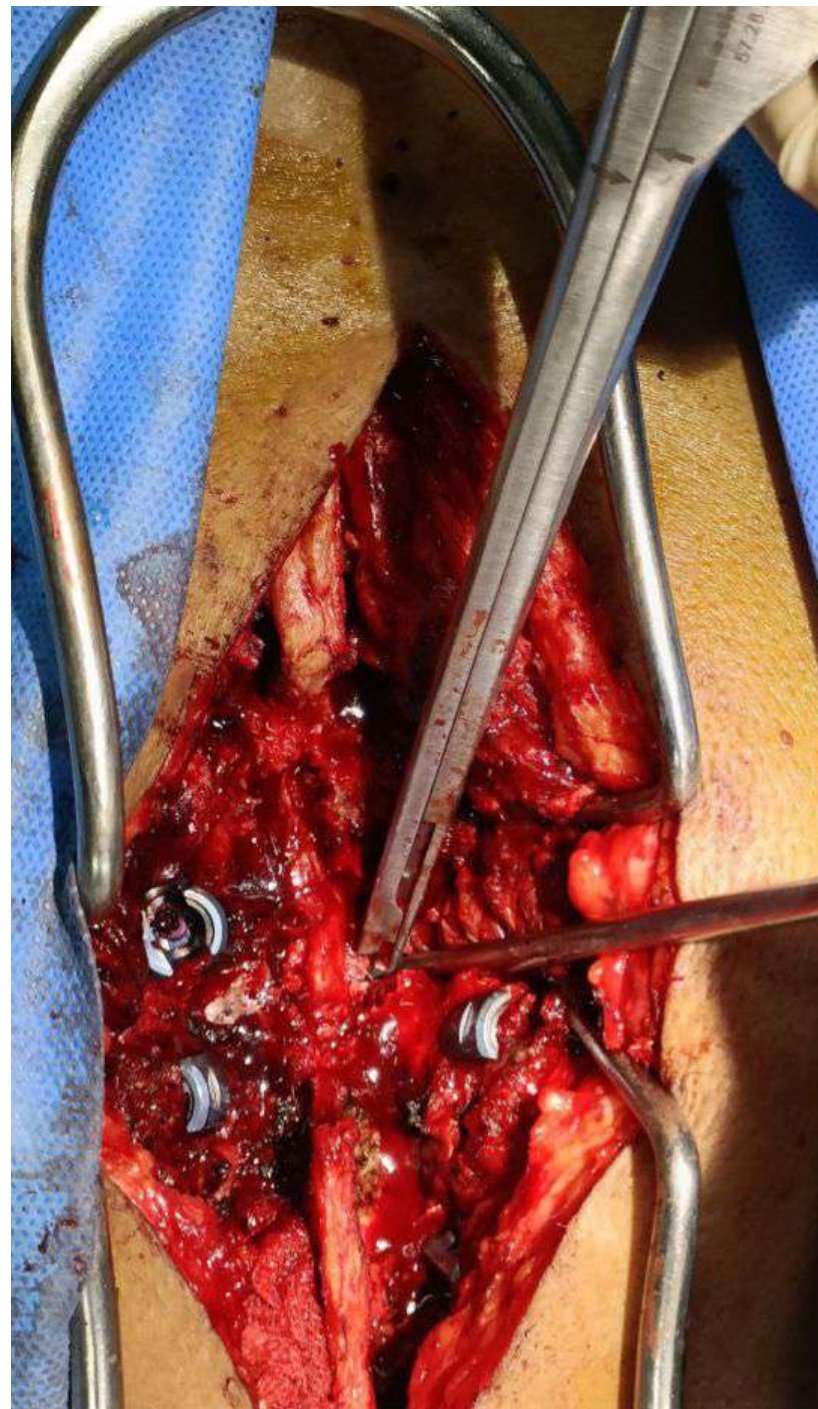
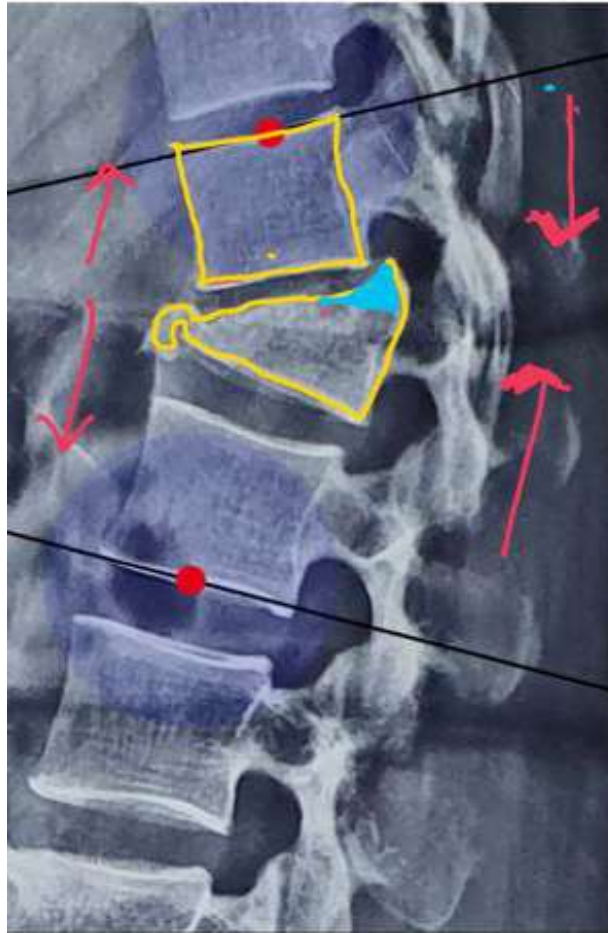
Bone Disc Bone Osteotomy

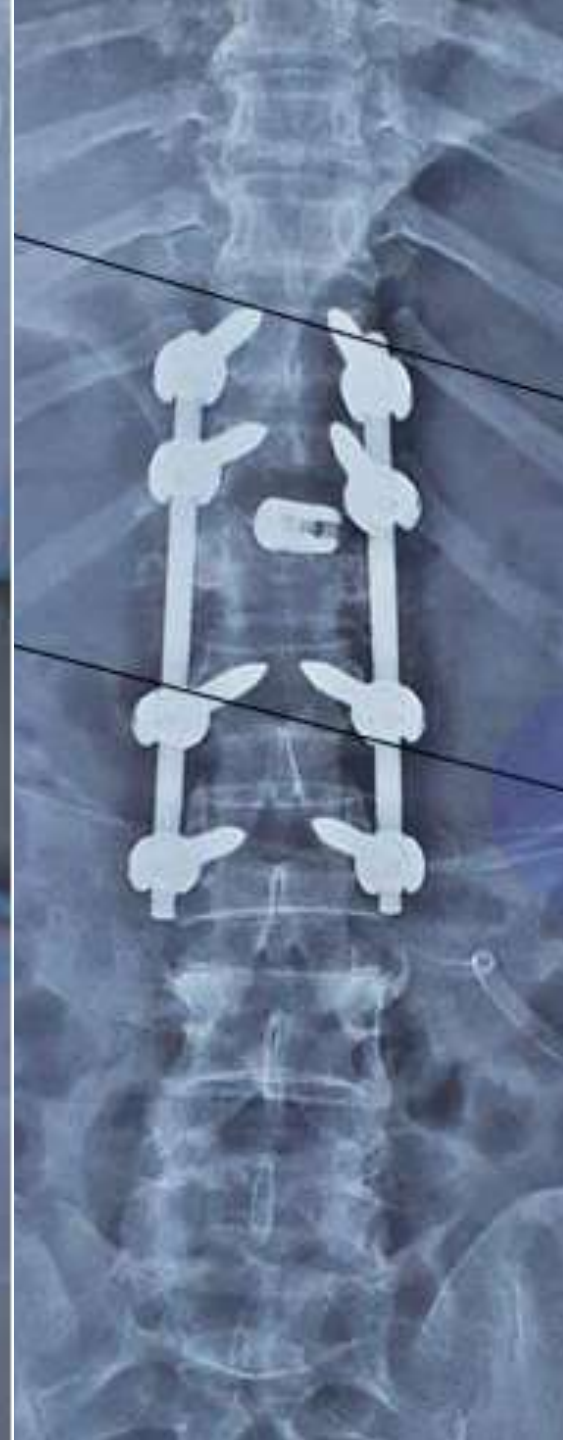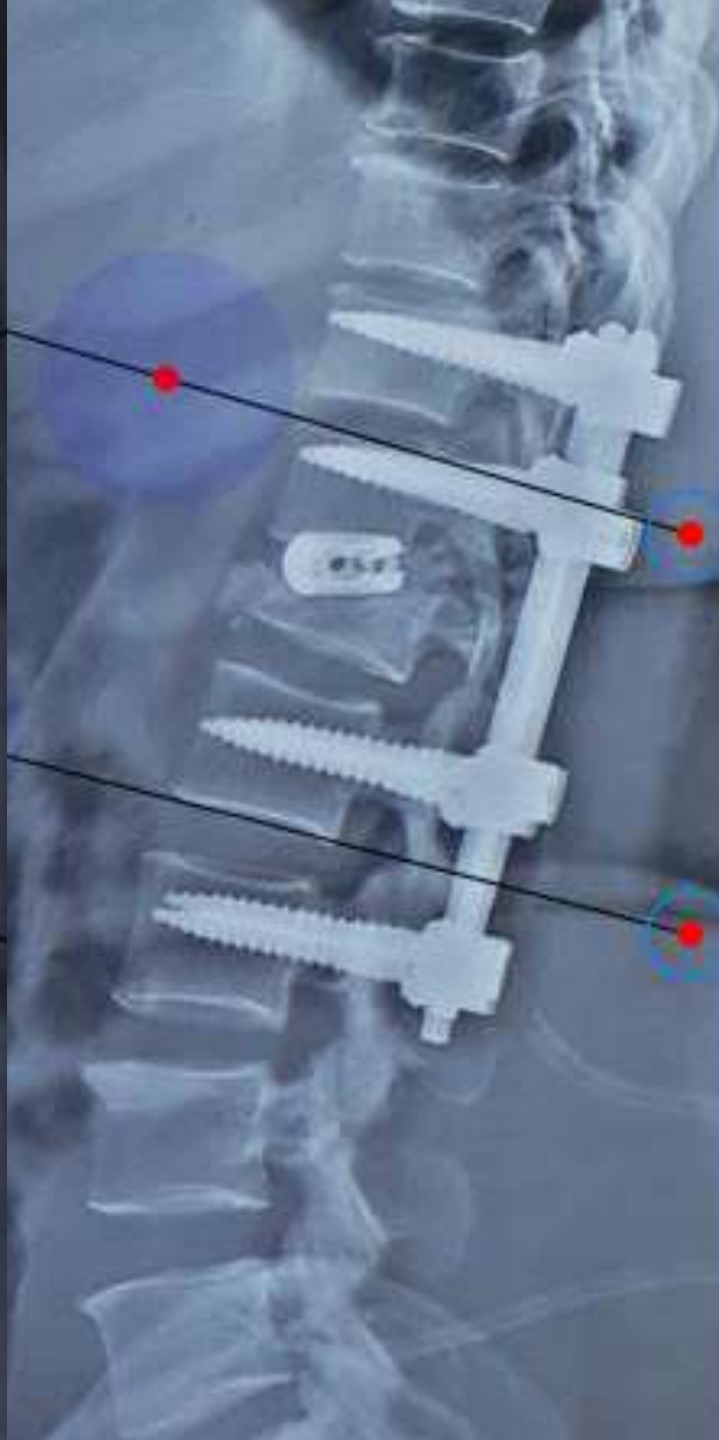
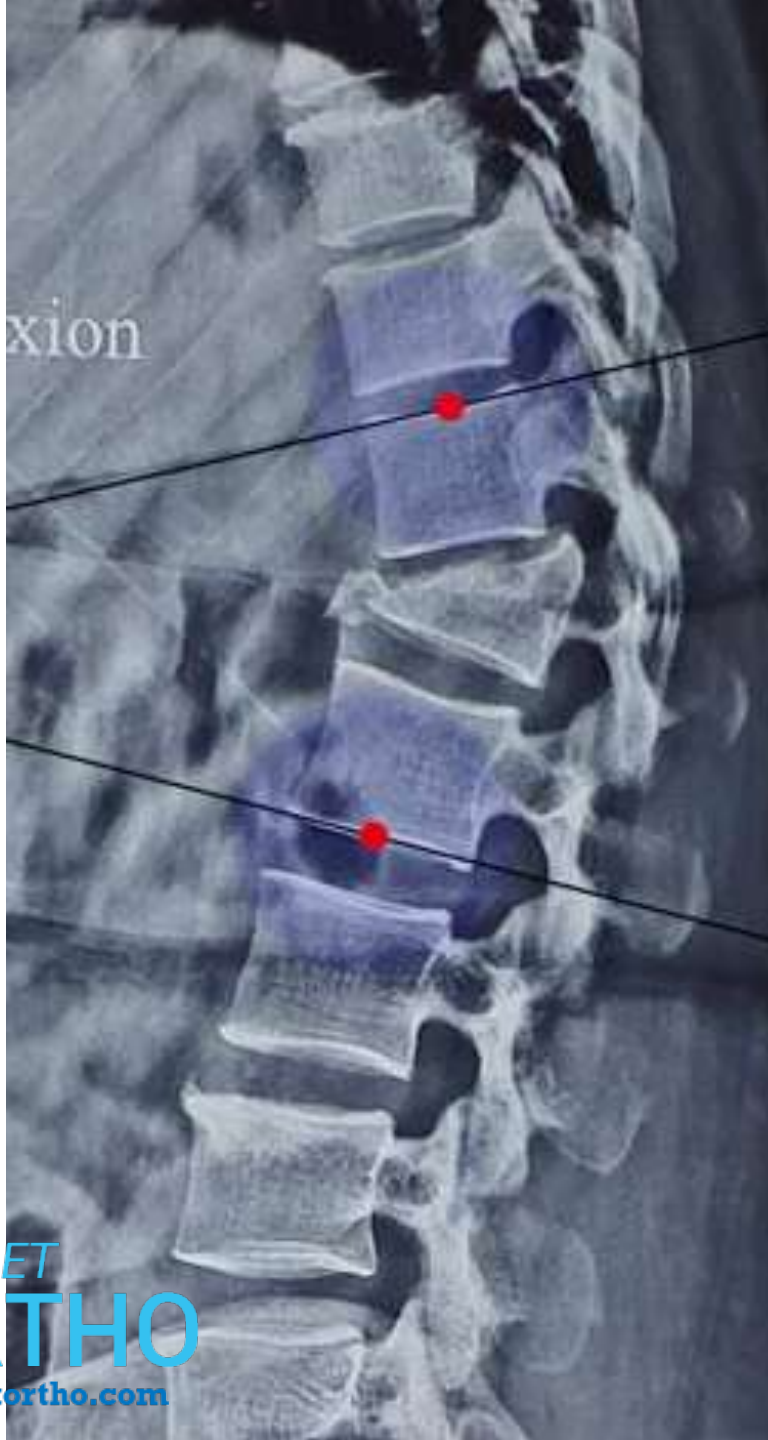
- Advantage
 - Correction of deformity at the CORA
 - More correction than PSO
- Limitation:
 - Not possible when anterior disc is calcified (Eg: SpA)







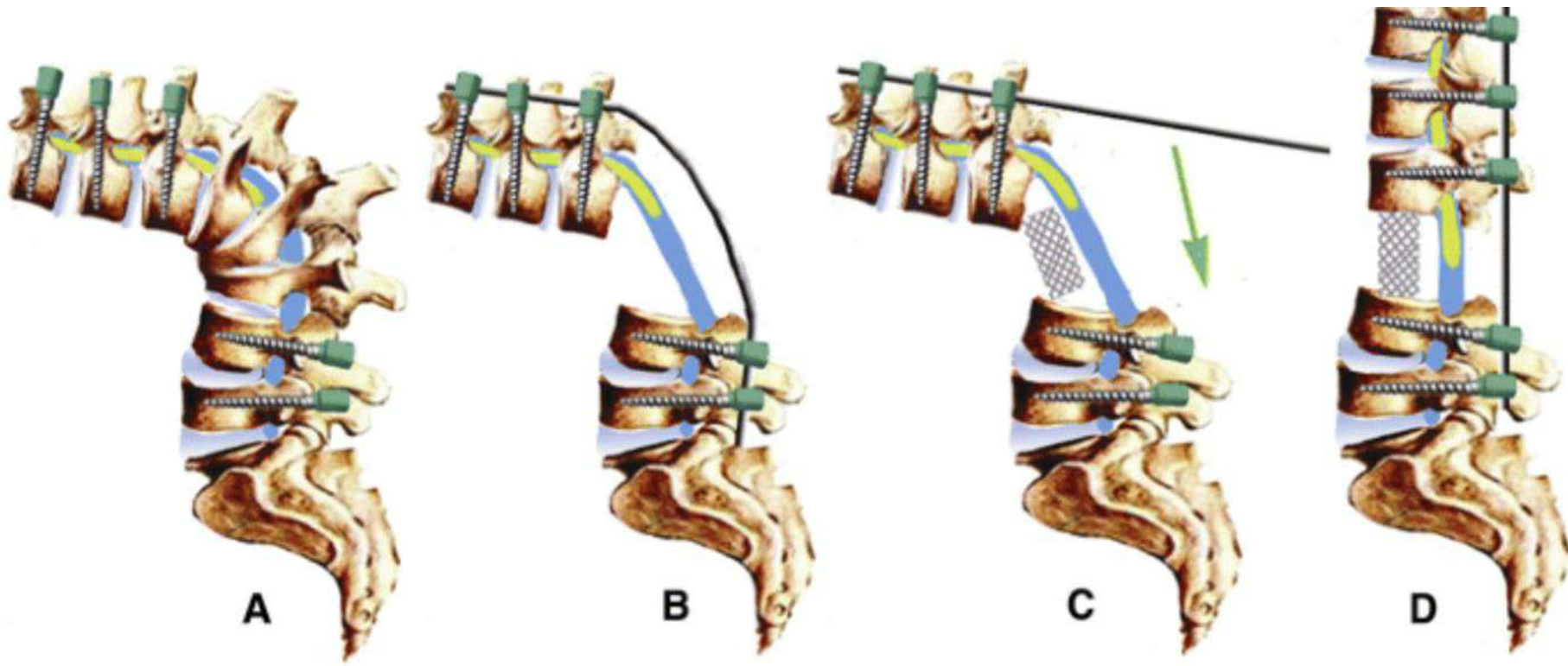




Bone Disc Bone Osteotomy

- Pitfalls
 - Vascular Damage
 - Steep learning curve

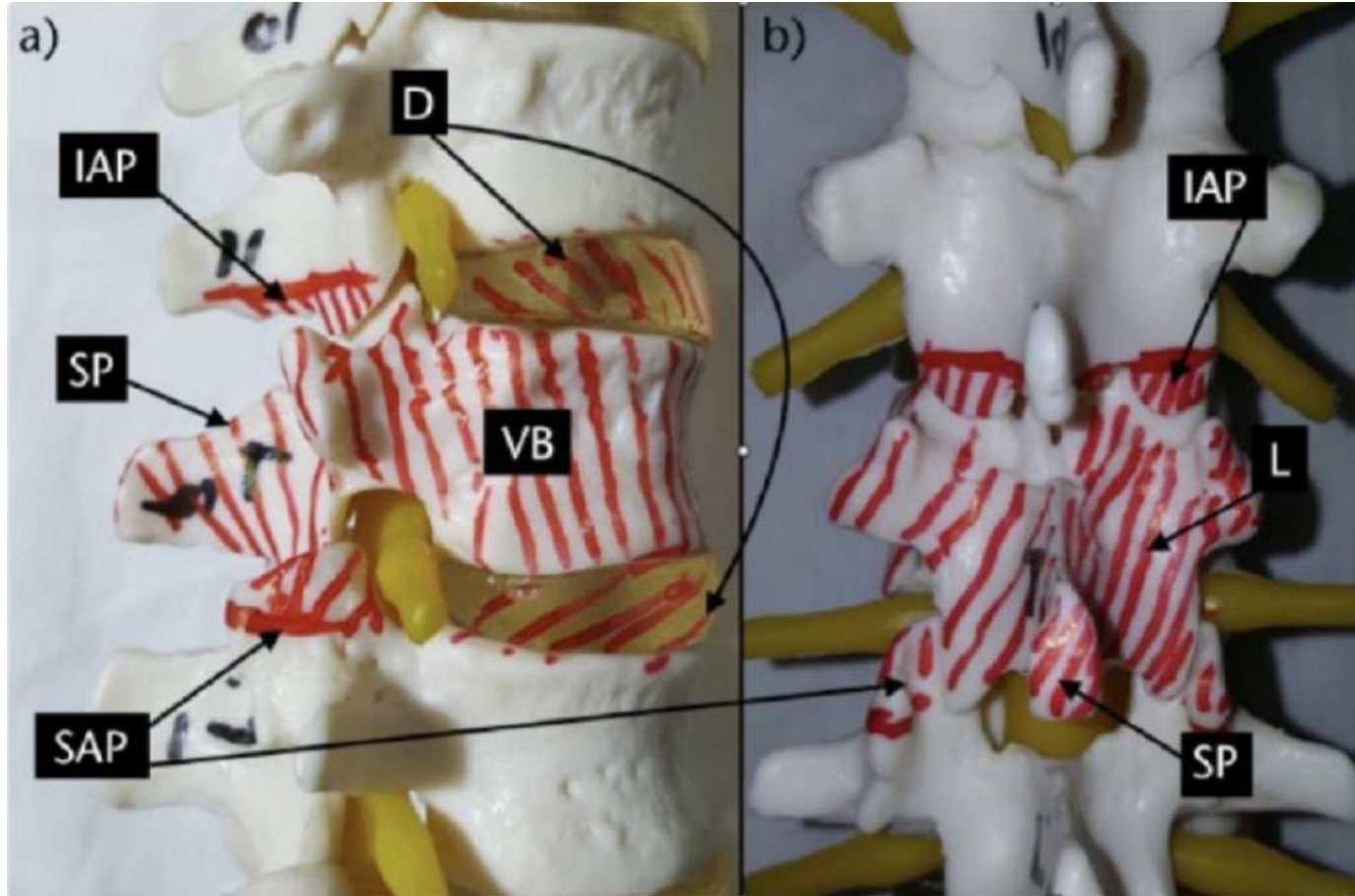
Vertebral Column Resection



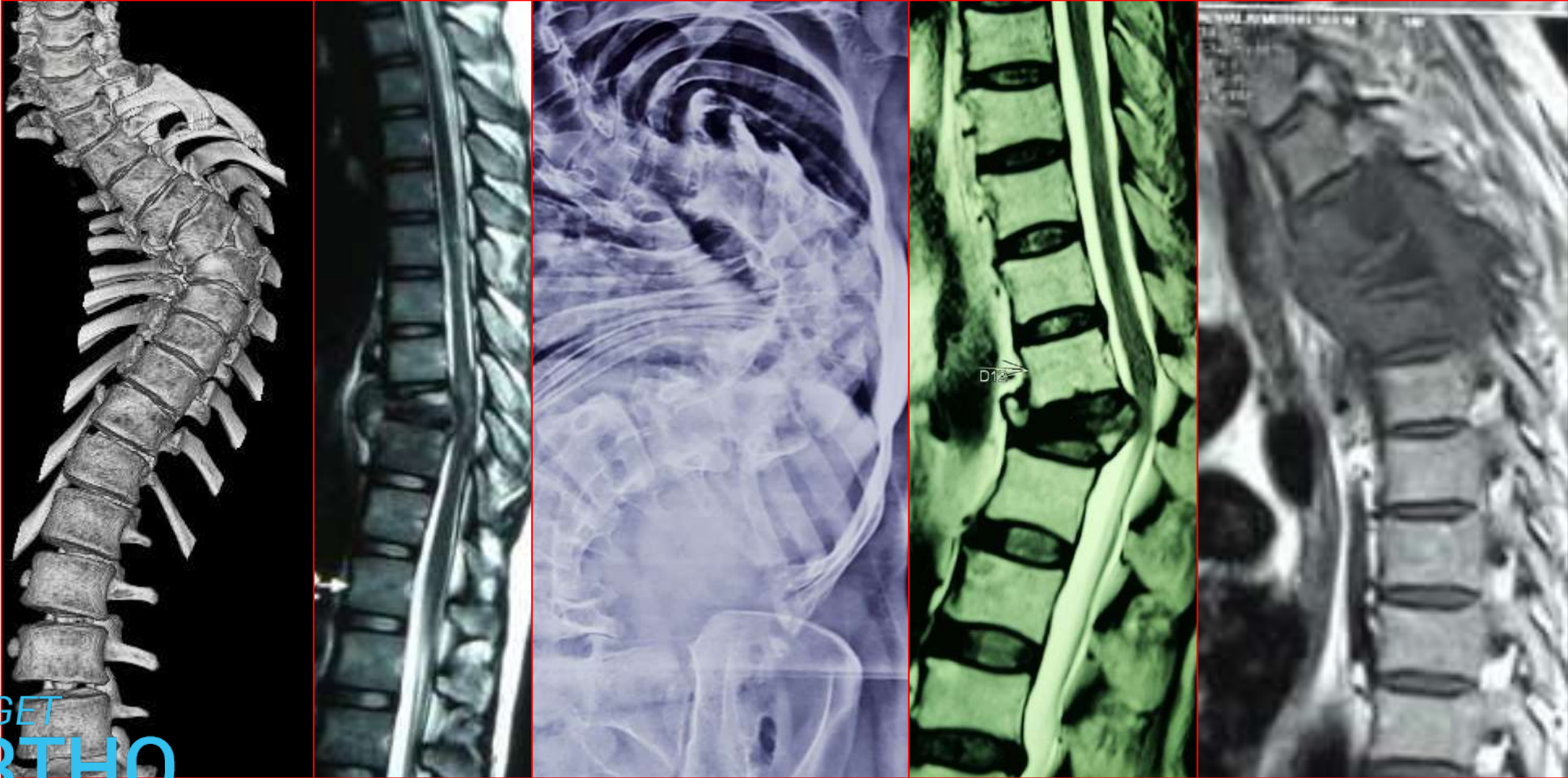Vertebral Column Resection

- rigid multiplanar deformities
 - sharp angular deformities
 - hemivertebra resection
 - spinal tumours
-
- circumferential vertebral column resection
 - concave rib osteotomies
 - convex thoracoplasty
 - segmental spinal instrumentation with fusion

Vertebral Column Resection



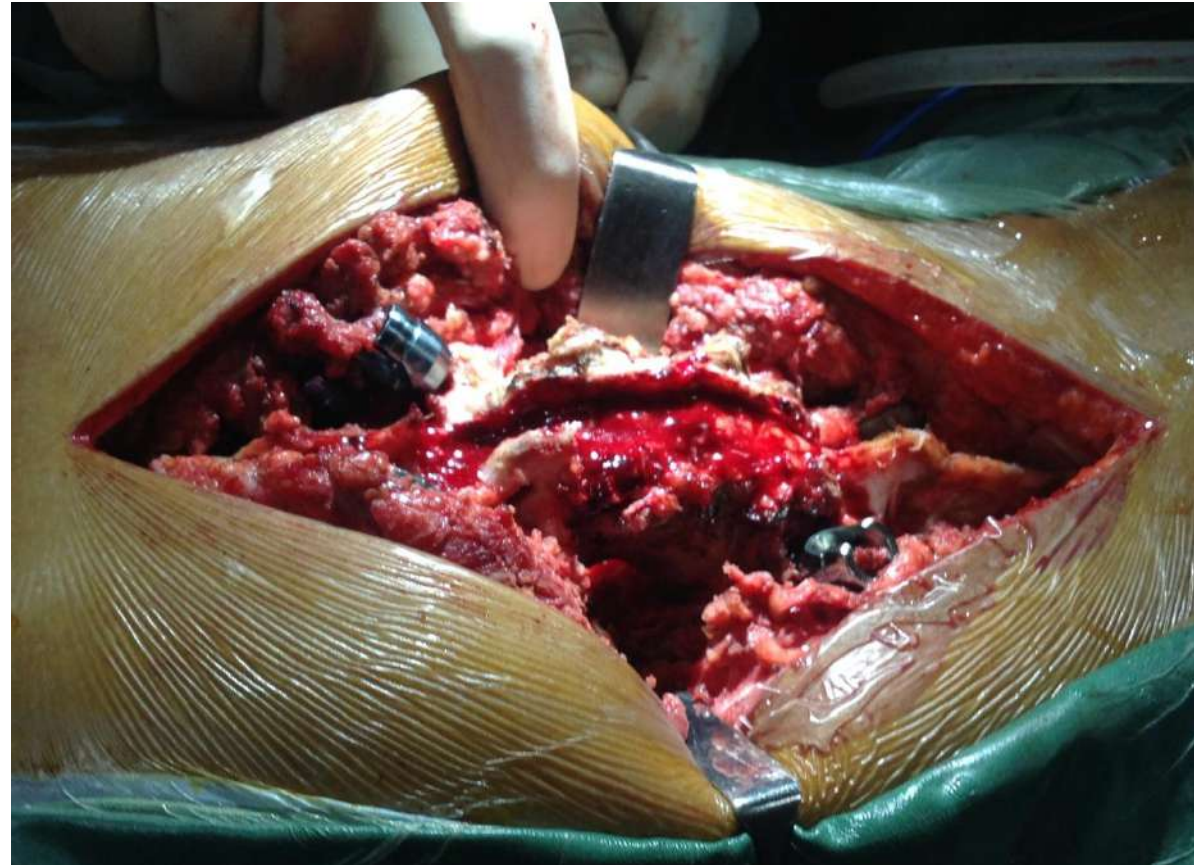
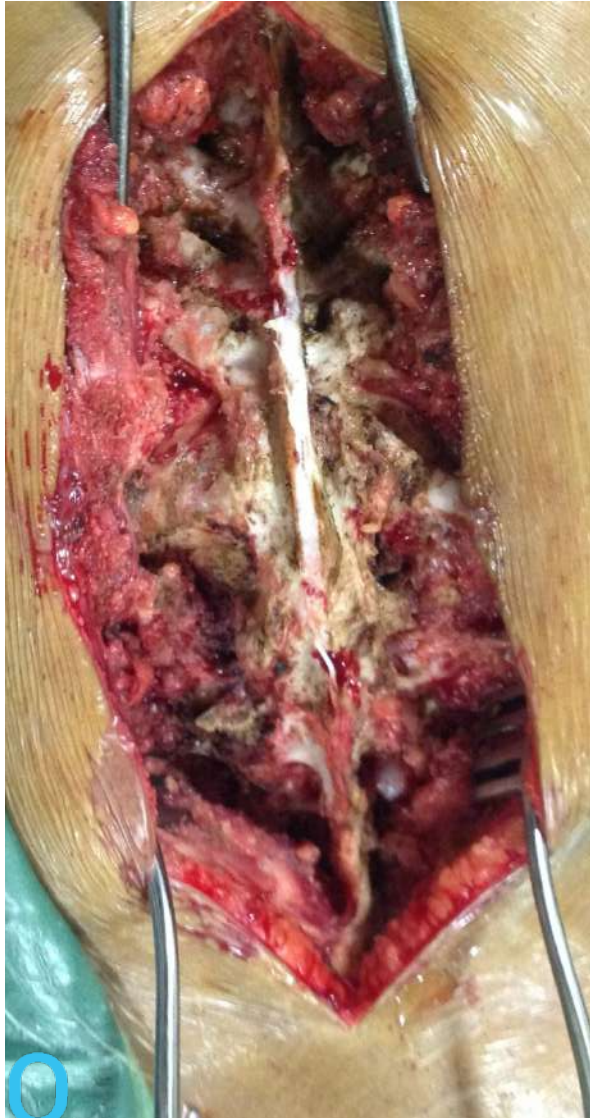Vertebral Column Resection



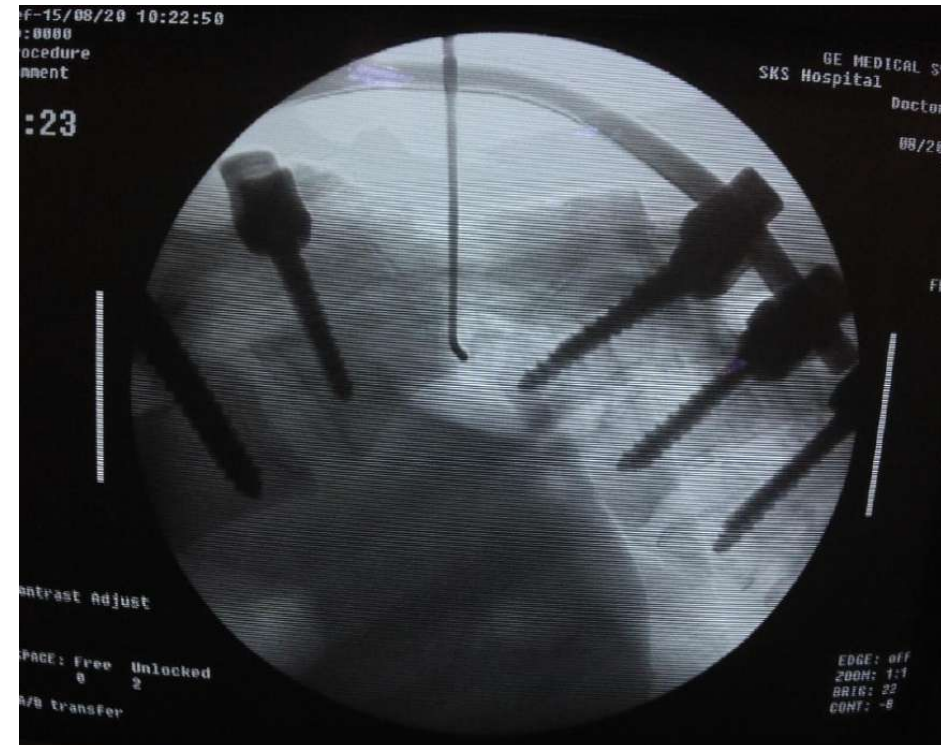
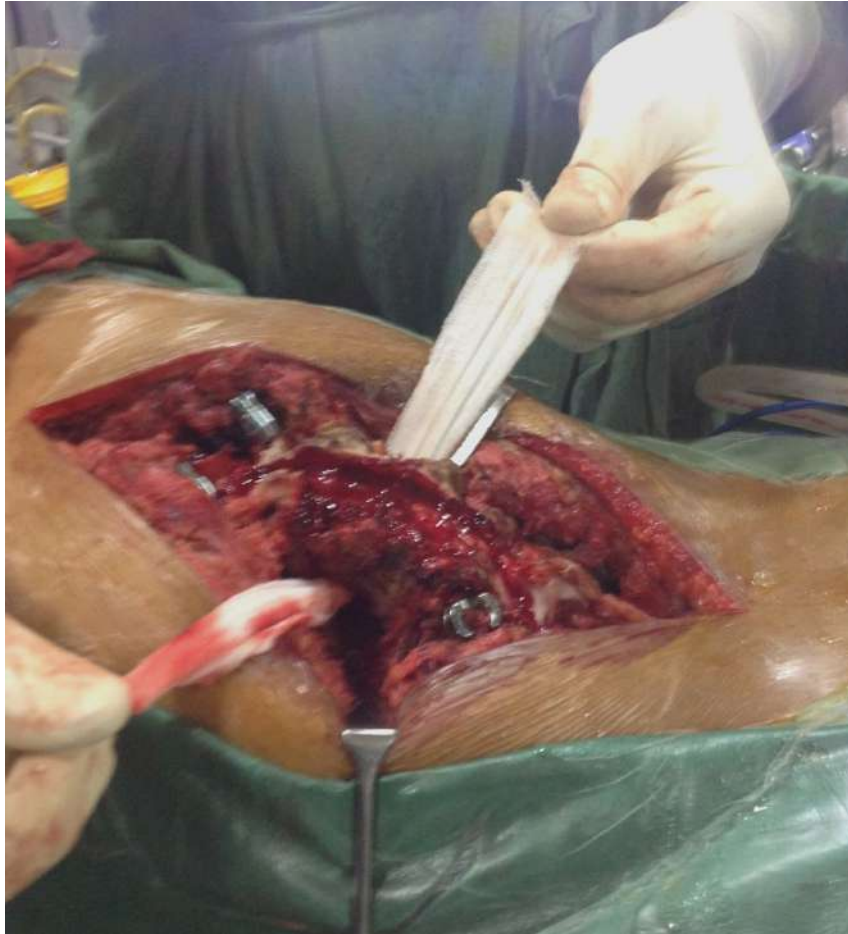Vertebral column resection(VCR)

- Powerful tool for correction of rigid spinal deformities
- Anterior + Posterior circumferential VCR- late 1980s
- Posterior VCR(PVCR)

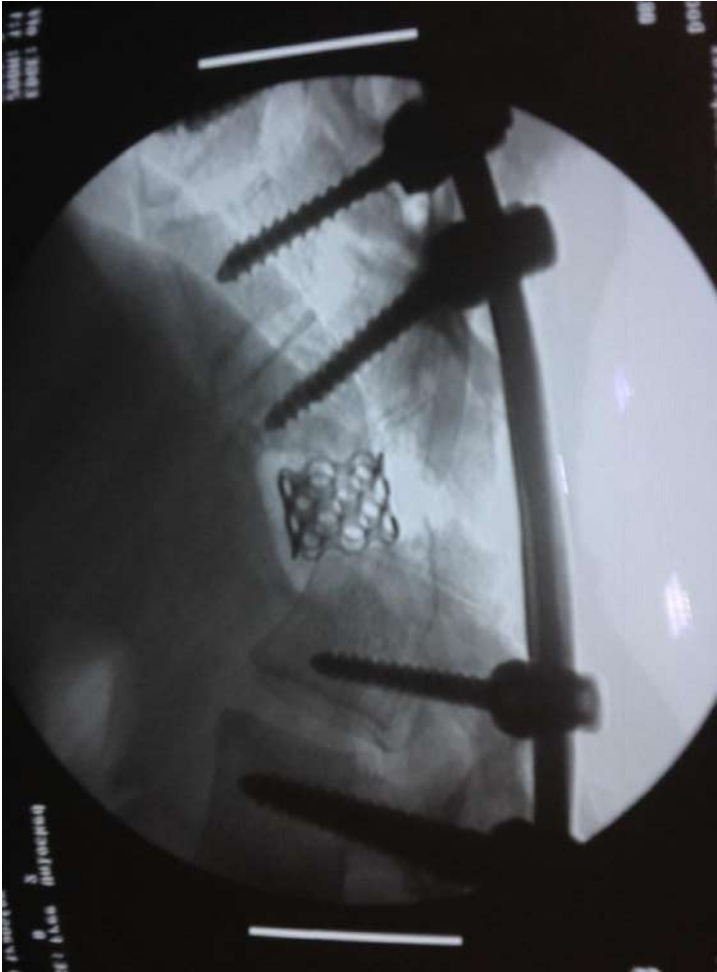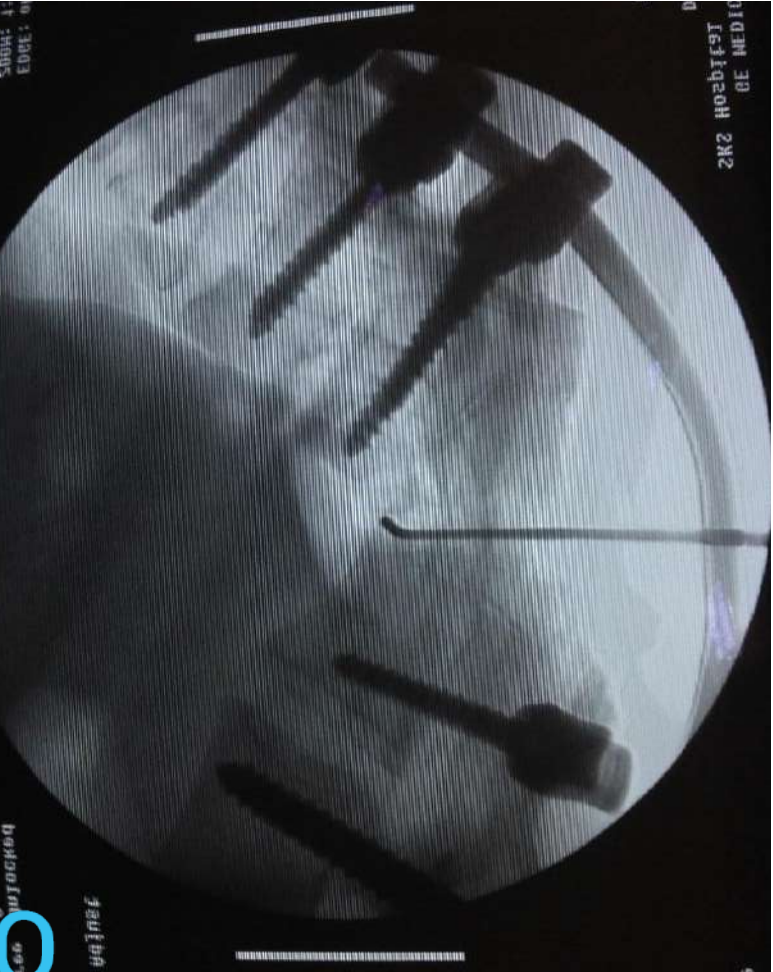Surgical procedure



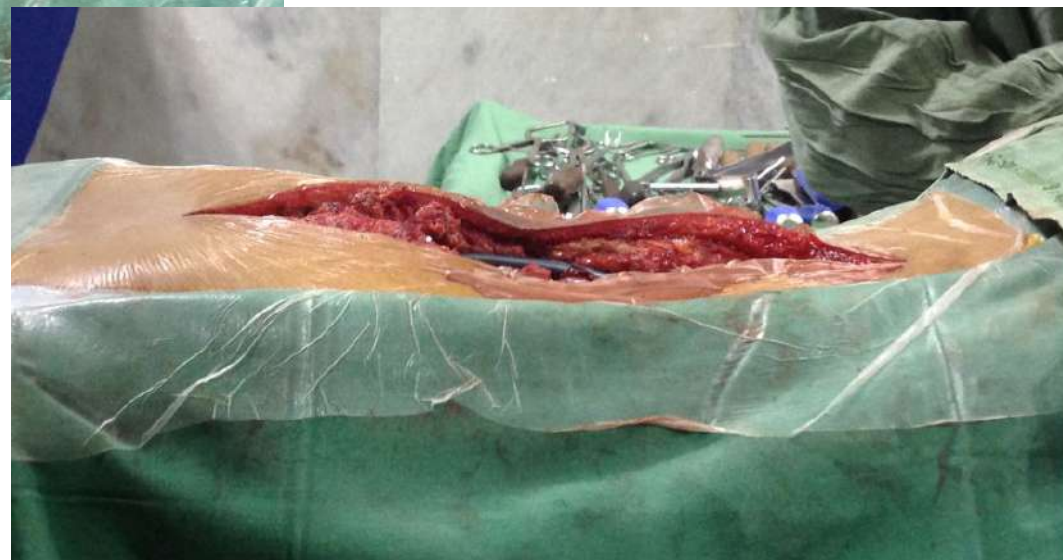
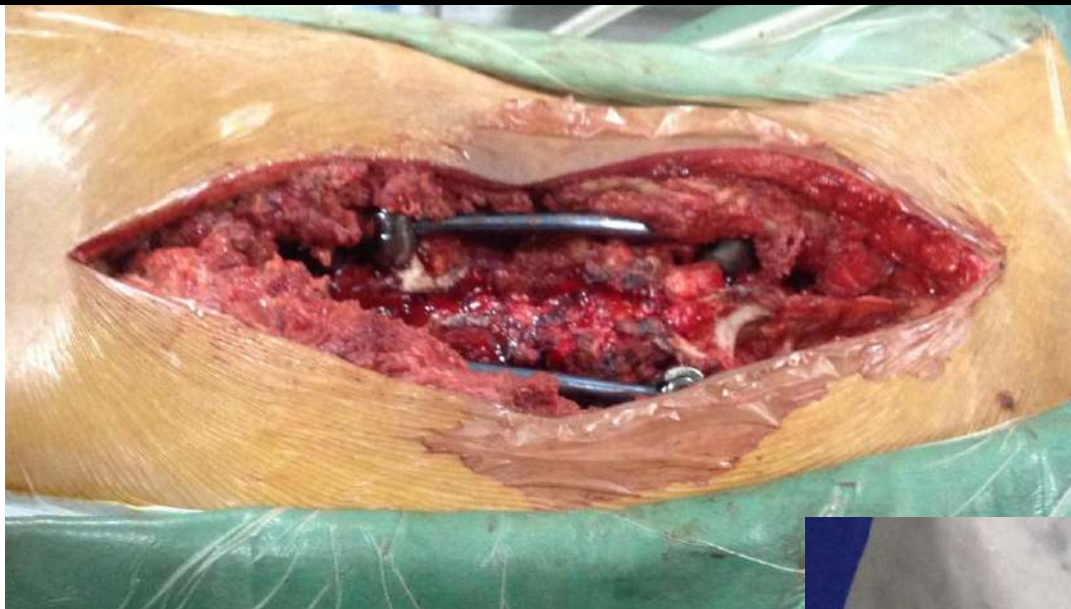Surgical procedure



Vertebral Column Resection

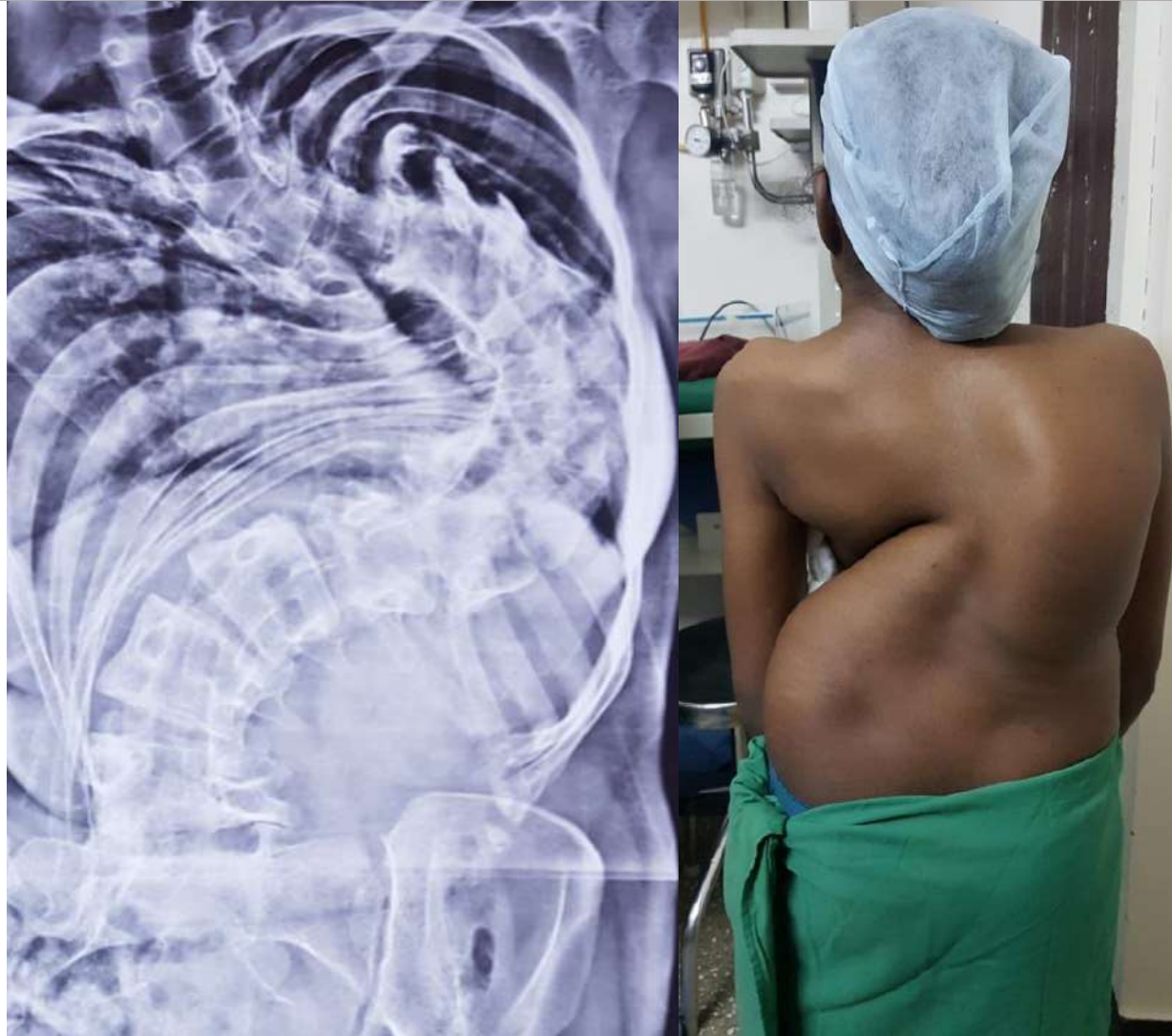

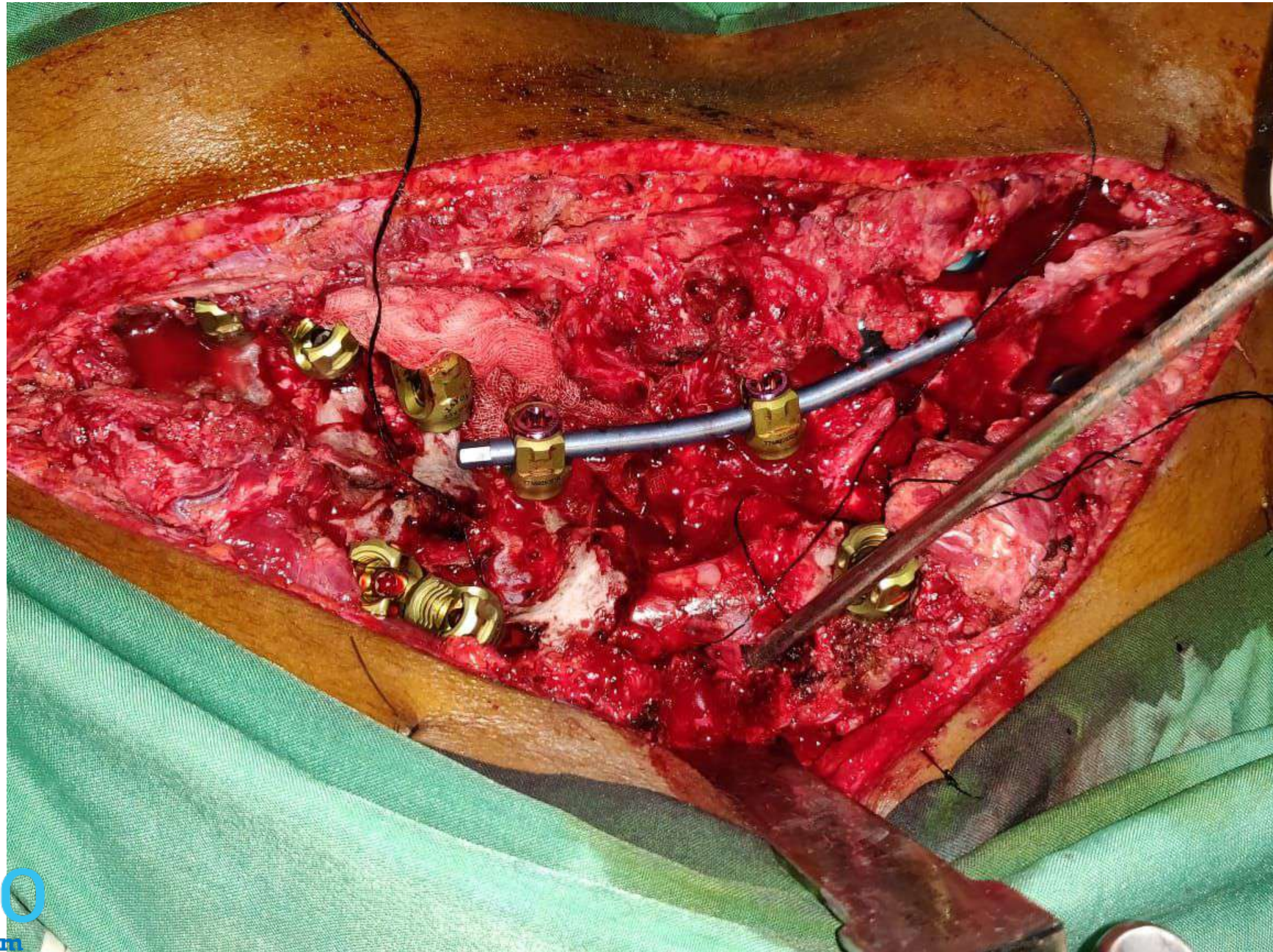
Surgical procedure

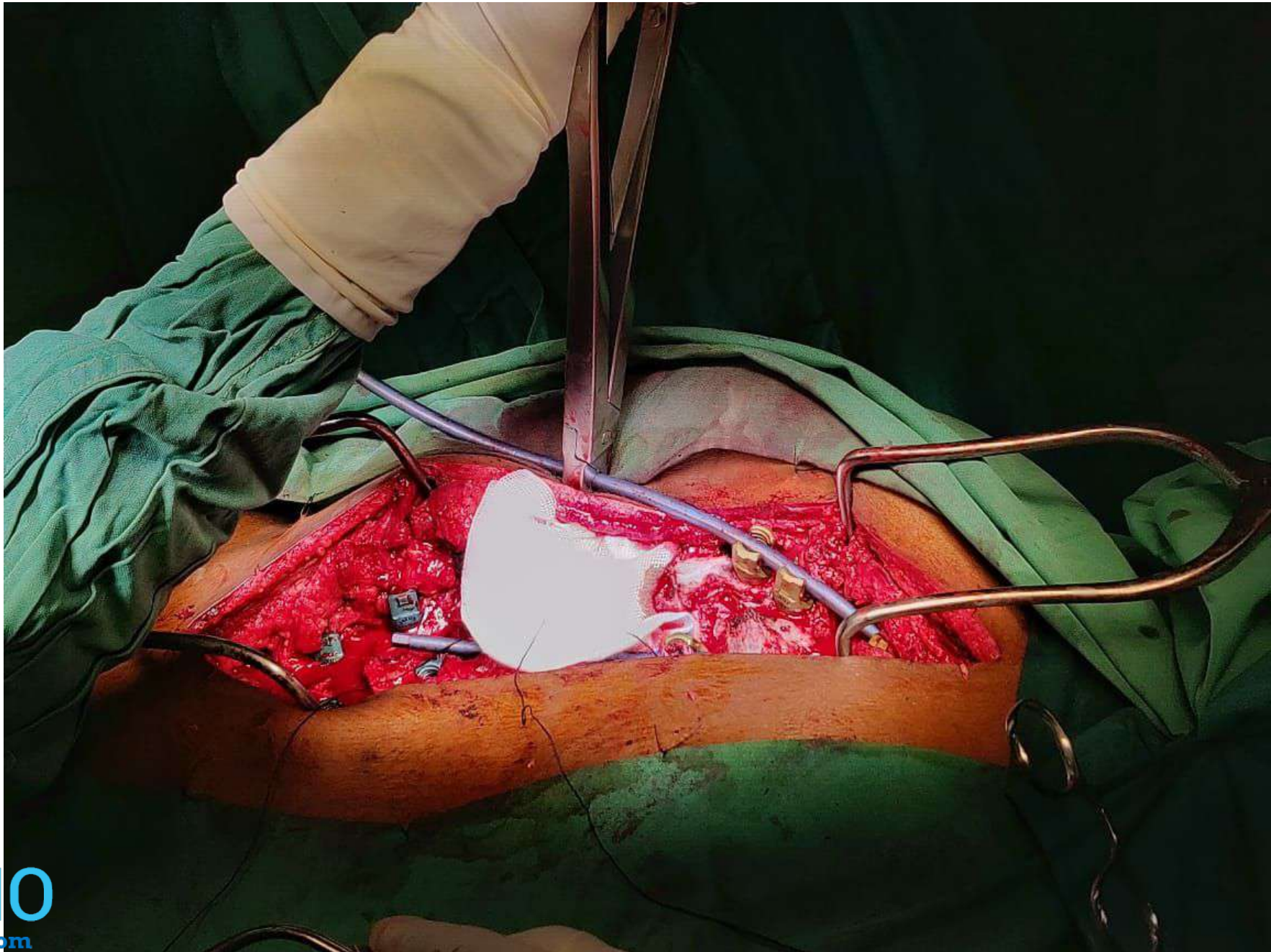


Case

Severe rigid scoliosis

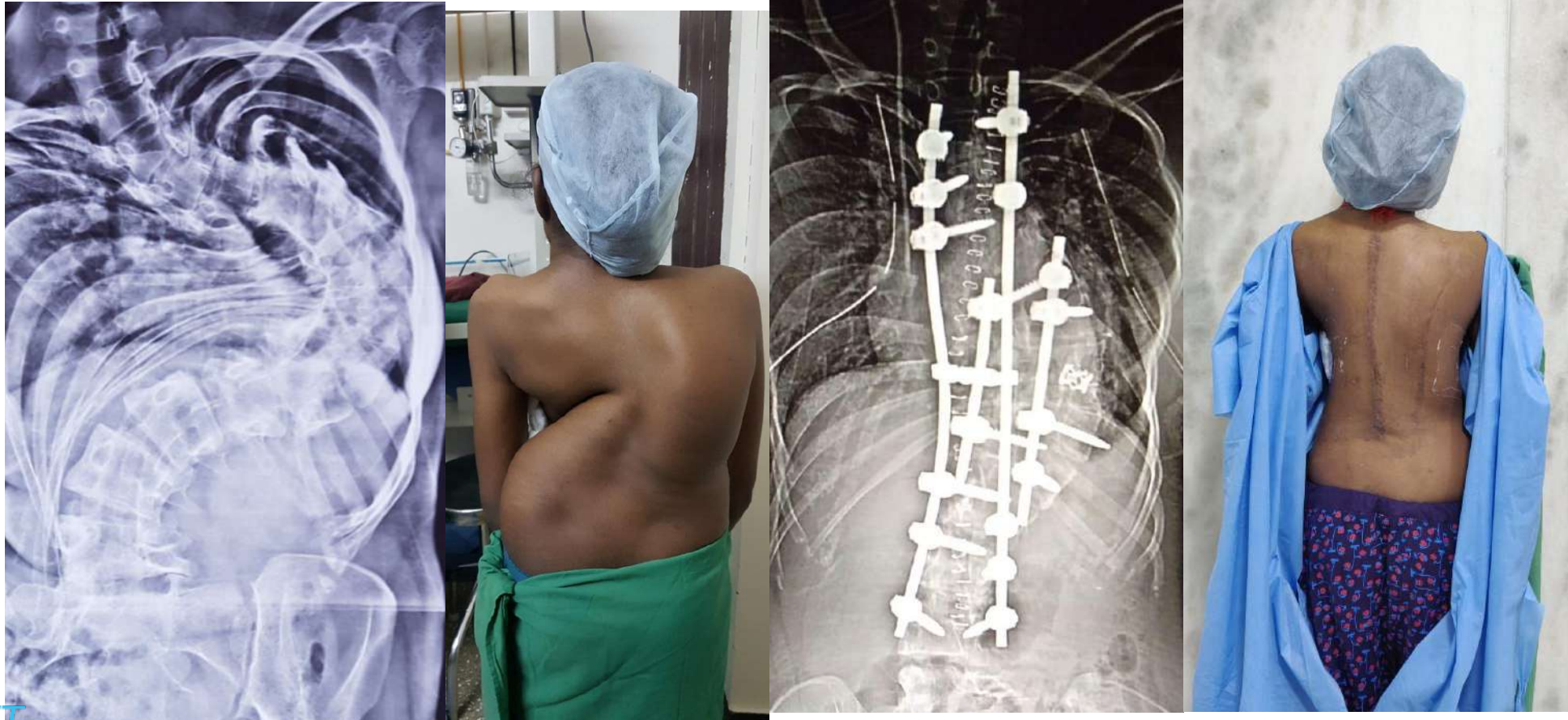






Case

Severe rigid scoliosis



Vertebral Column Resection

- Average Correction : 60 deg coronal / 70 deg sagittal

Vertebral Column Resection

- Pitfalls
 - Extensive procedure
 - Blood loss upto 5L
 - Neurodeficit
 - Translation injury to cord
 - Delayed Neurodeficit due to subluxation of spinal column
 - More chance of deficits in Myelopathy patient

[J Bone Joint Surg Am.](#) 2018 Jul 5; 100(13): 1147–1156.

Published online 2018 Jul 5. doi: [10.2106/JBJS.17.01127](https://doi.org/10.2106/JBJS.17.01127)

PMCID: PMC6075880

PMID: [29975269](https://pubmed.ncbi.nlm.nih.gov/29975269/)

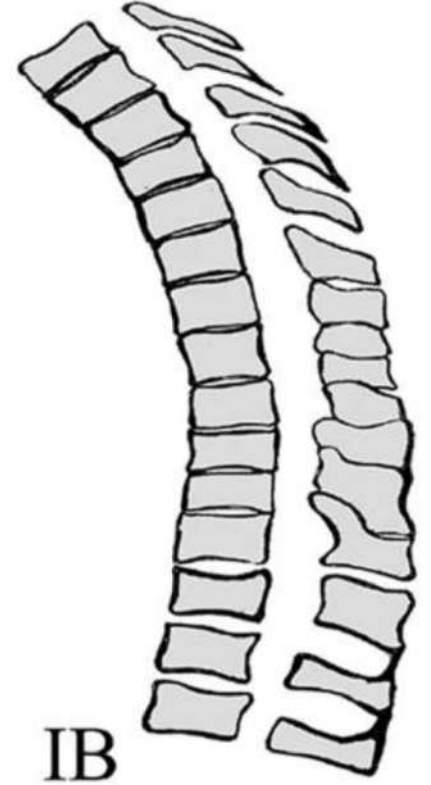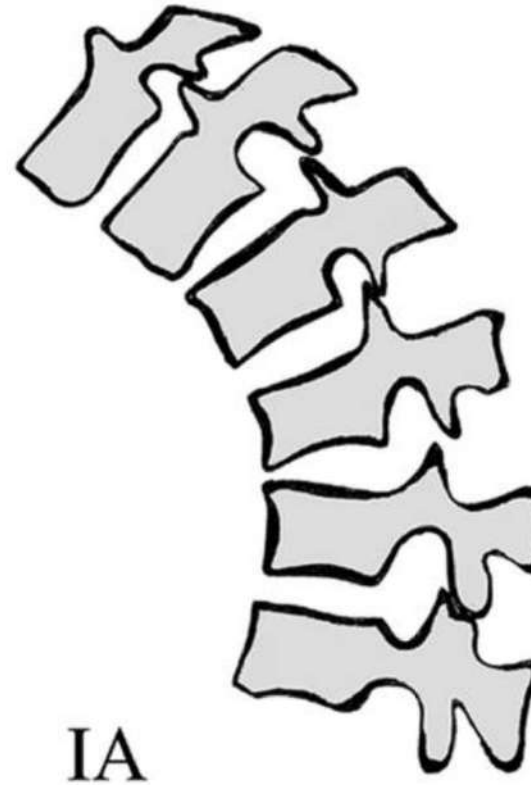A Classification for Kyphosis Based on Column Deficiency, Curve Magnitude, and Osteotomy Requirement

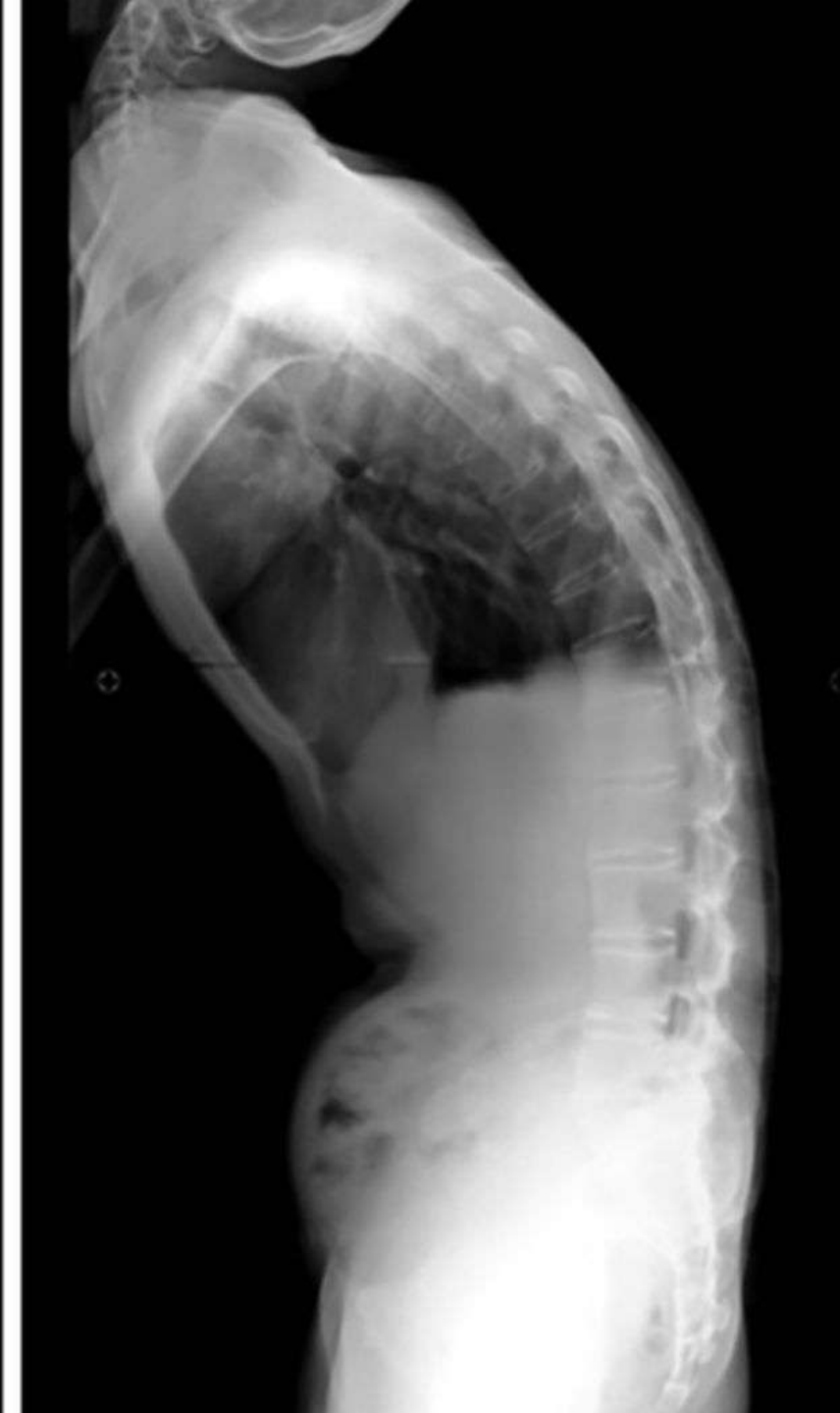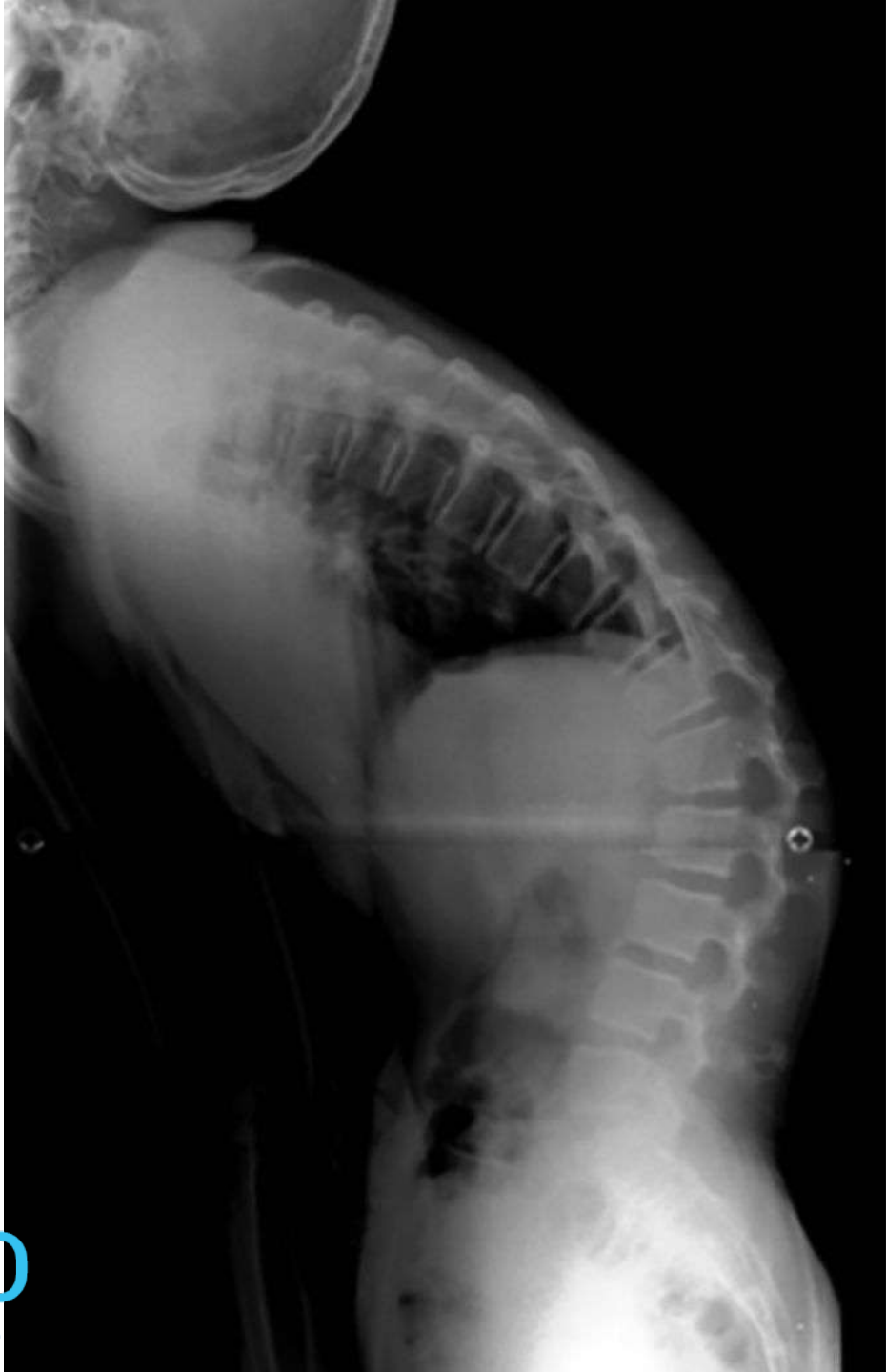[S. Rajasekaran](#), MS, FRCS, MCh, PhD,^{1,a} [Sreekanth Reddy Rajoli](#), MS, FNB,¹ [Siddharth N. Aiyer](#), MS, FNB,¹
[Rishi Kanna](#), MS, FNB, MRCS,¹ and [Ajoy Prasad Shetty](#), MS¹

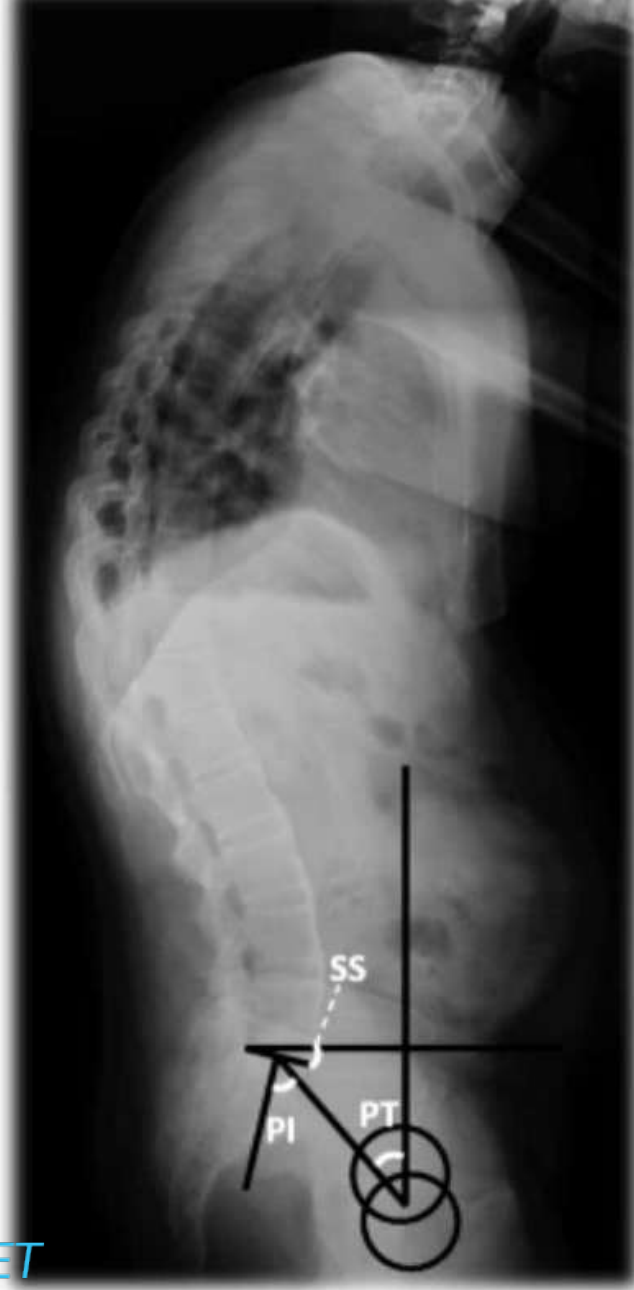▶ [Author information](#) ▶ [Copyright and License information](#) ▶ [Disclaimer](#)

Kyphosis : 3 types

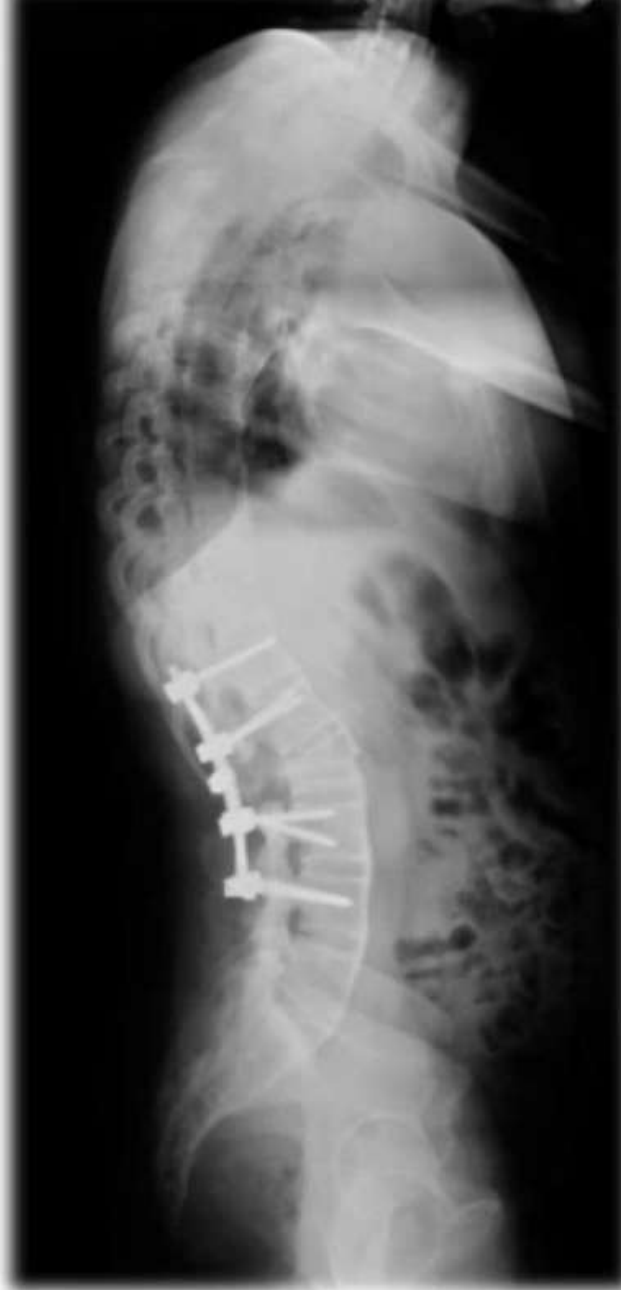- Type I : Both Columns Intact
 - IA : Mobile Disc segments
 - IB : Fixed Kyphosis with Ankylosed Spaces



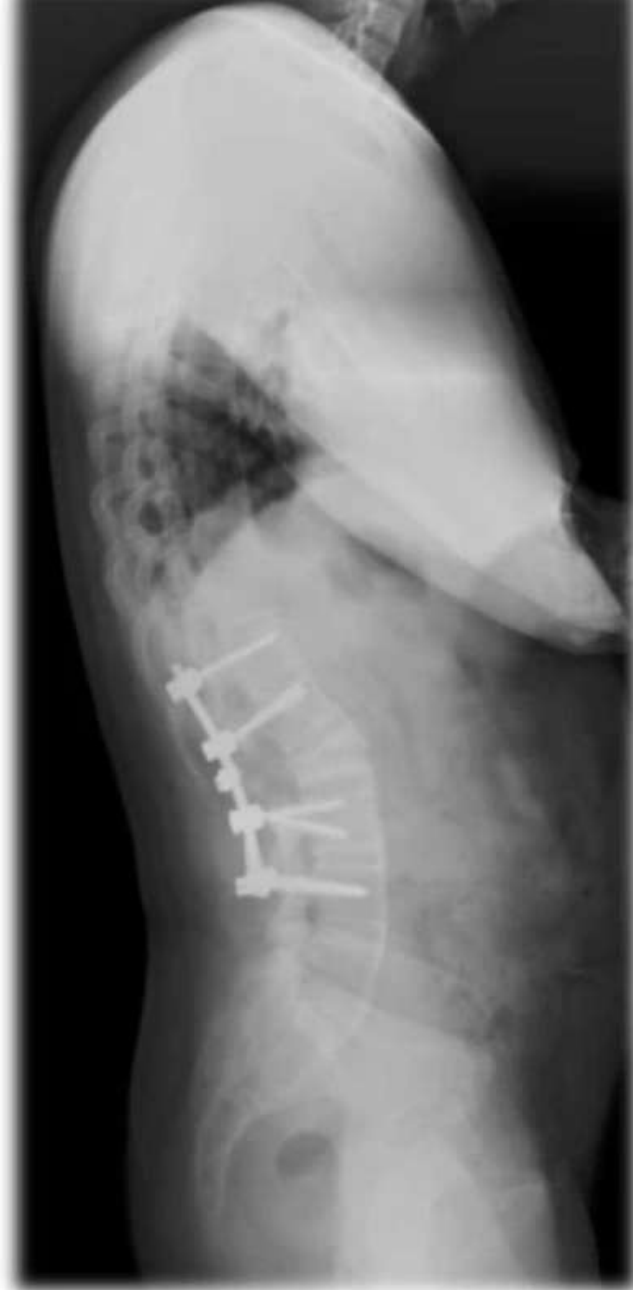



Pre-op



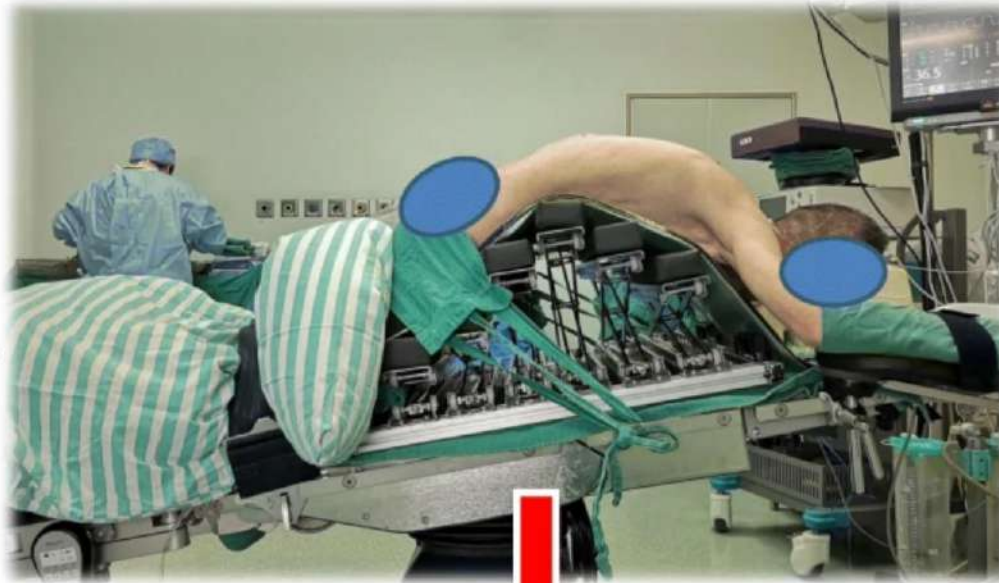
Post-op



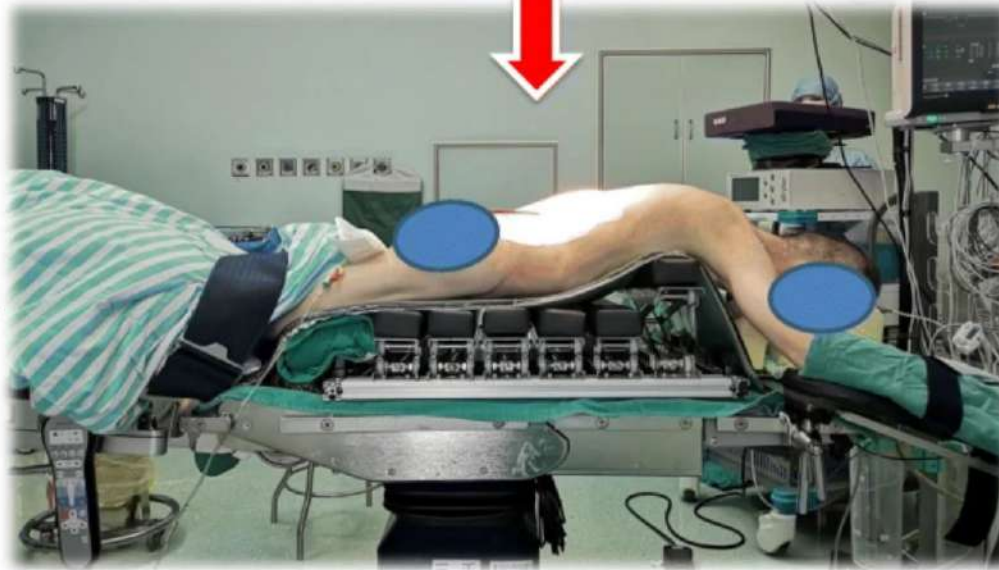
2-year

Fig. 2

Before
surgery



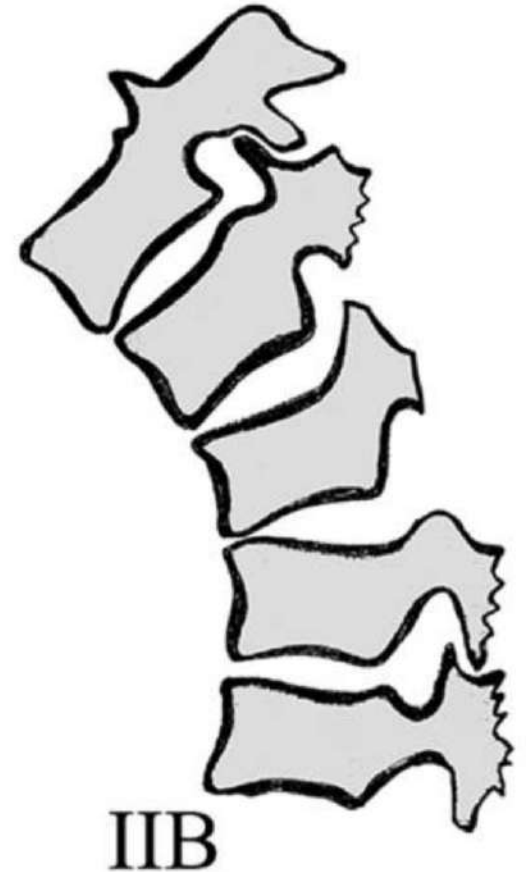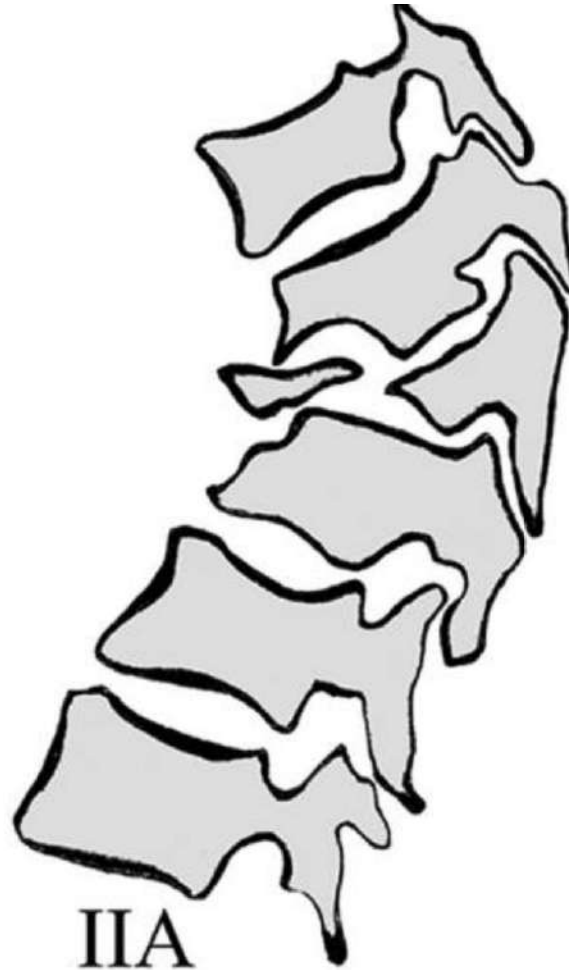
After
surgery



Modified Operating Table

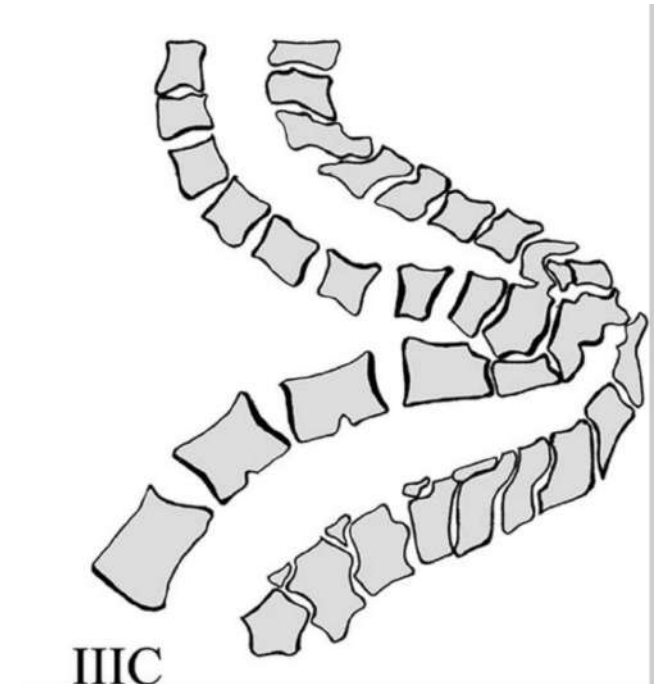
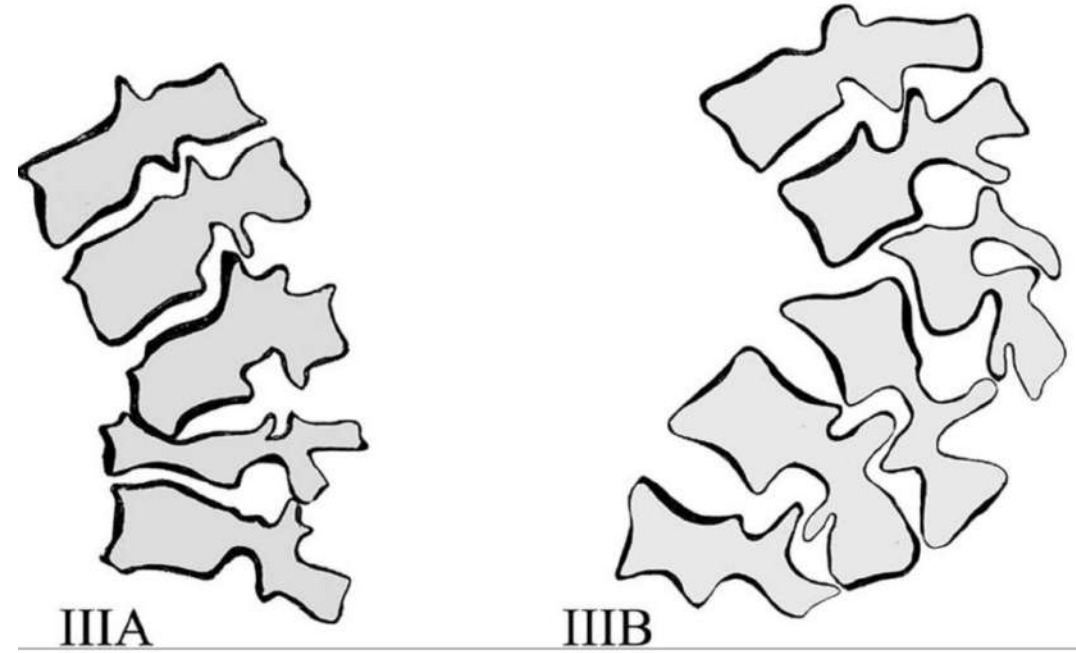
Type II : One Column Deficient

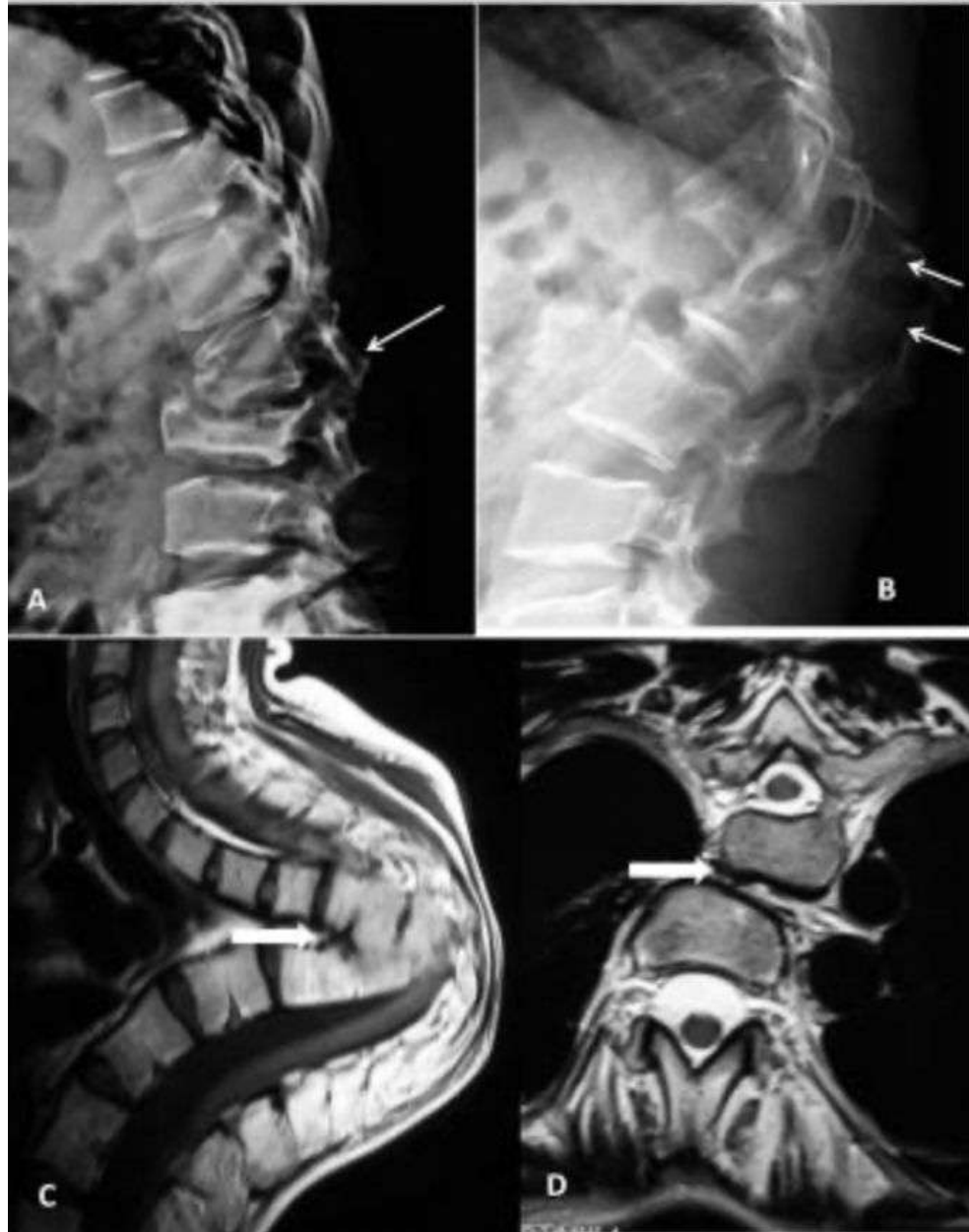- IIA : Anterior Column Deficient
- IIB : Posterior Column Deficient



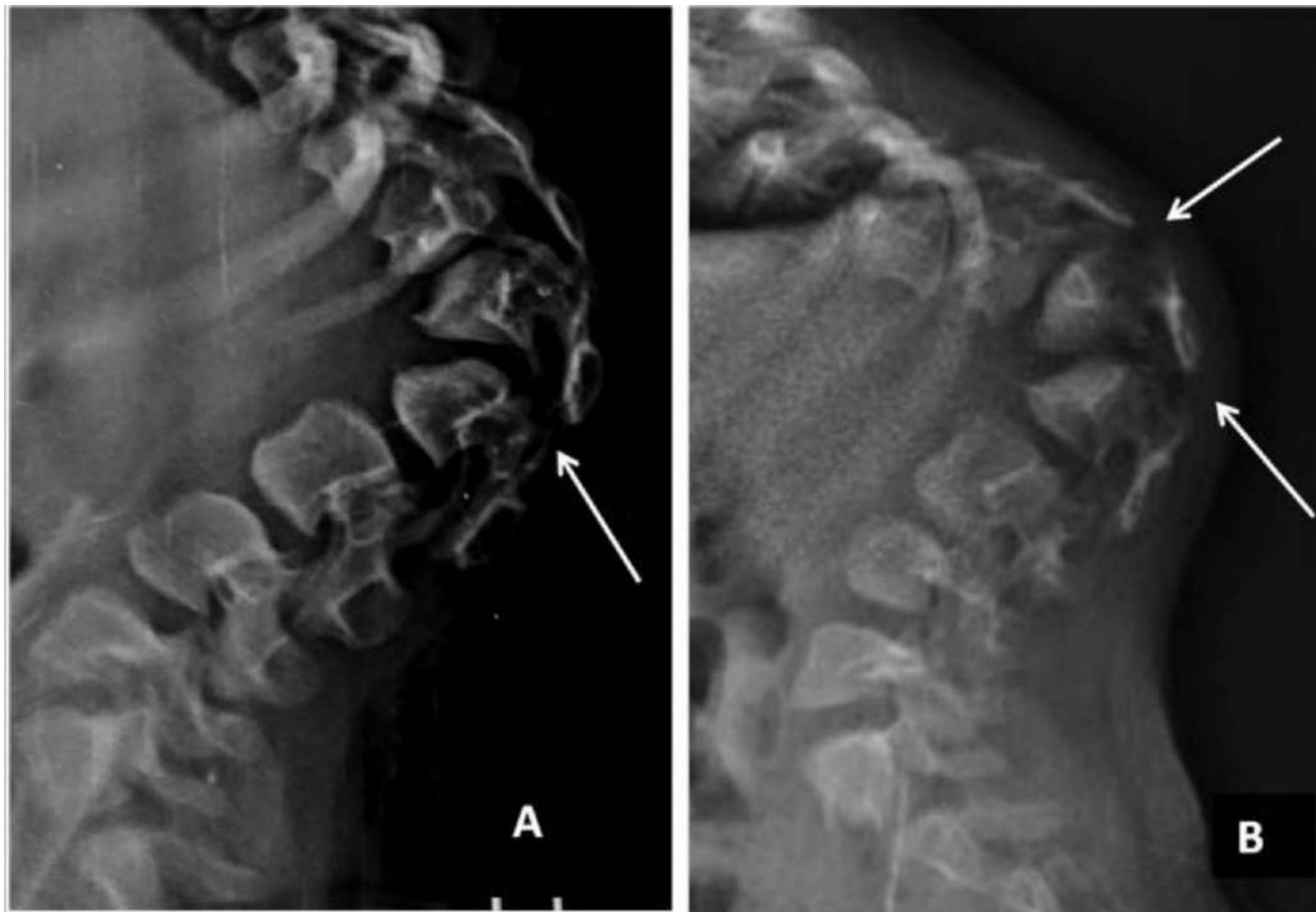
Type III : Both Columns Deficient

- IIIA : Kyphosis $< 60^\circ$
- IIIB : Kyphosis $> 60^\circ$
- IIIC : Buckling Collapse

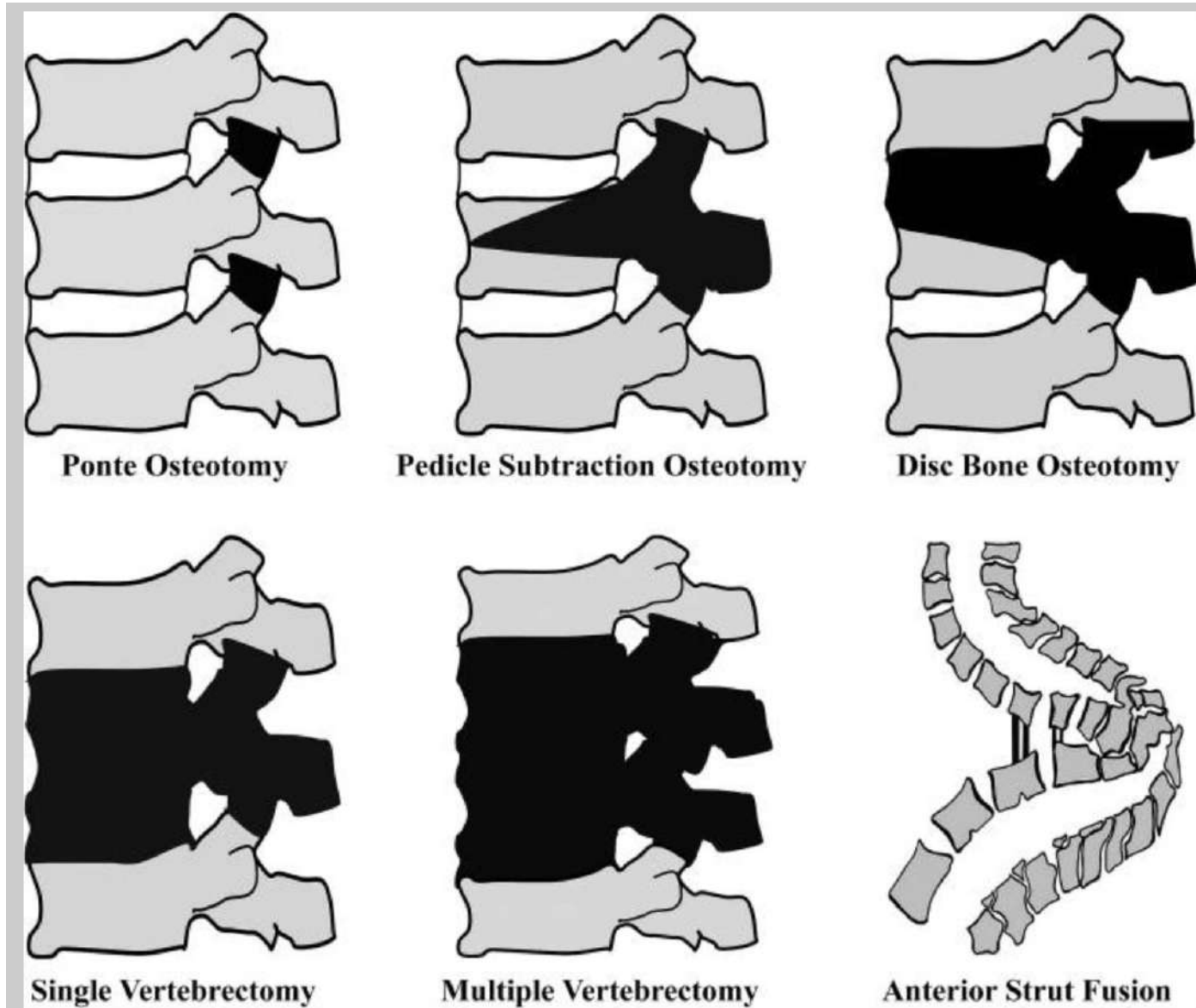




- Anterior Column Deficiency :
 - Structural loss of bone/disc or both
- Posterior Column Deficiency :
- Structural failure caused by failure of posterior ligamentous structure
- Functional failure caused by gradual facet joint subluxation



5 Osteotomies of increased complexity



Surgical Algorithm

